

Misheelt Bayarsaikhan^{1,✉} Kenji Okazaki²

¹Institute of Archaeology,
Mongolian Academy of Sciences Building-1,
Peace avenue, Ulaanbaatar-13330, Mongolia

²Department of Anatomy, Faculty of Medicine, Tottori University
86 Nishi-cho, Yonago 683-8503, Japan

A case of radioulnar synostosis of Mongolia

Abstract. In recent years, studies of ancient humans remain discovered during archaeological excavations have increased in Mongolia and significantly enhanced understanding of the lives and livelihoods of past populations there. The authors investigated one skeleton unearthed from Ulaanbulag macroscopically. This study describes a differential diagnosis of proximal radioulnar fusion seen in a male subadult from Ulaanbulag. This work recognizes the potential relevance of the first reported archaeological instance of congenital radioulnar synostosis (CRUS) in Mongolia and draw attention to this example's early date.

Keywords. Radioulnar synostosis, congenital radioulnar synostosis, paleopathology, Mongolia, Xiongnu

Баярсайханы Мишээлт^{1,✉}, Кенжи Оказак²

¹Монгол Улсын Шинжлэх ухааны Академийн Археологийн хүрээлэн,
Монгол улс, Улаанбаатар-13330, Энхтайвны өргөн чөлөө,
Шинжлэх Ухааны Академийн хүрээлэнгүүдийн нэгдсэн I байр

²Япон улс, Ёнаго хот, Ниши-ко, Тоттори их сургууль,
Анагаахын сургууль, Анатомийн тэнхим

Монгол нутгаас илэрсэн эртний хүний олдвор дээрх радиоулнар синостозын тохиолдол

Товчлол. Археологийн малтлага судалгаагаар илэрсэн эртний хүний ясны олдворуудыг судлах палеоантропологийн судалгаа сүүлийн жилүүдэд манай улсад эрчимжиж байгаа нь аливаа эртний соёлыг тээгчдийн амьдрал ахуйн талаарх ойлголтыг нэмэгдүүлэхэд зохих хувь нэмрийг оруулж байна. Энэхүү өгүүлэлд Сэлэнгэ аймгийн Ерөө сумын Улаанбулагаас илэрсэн хүүхдийн ясны олдвороос ажиглагдах богтос шуу 2 ясны нийлэгжилтийг өөр өөр оношоор тайлбарлана. Энэхүү өгүүлэл нь Монголоос илэрч буй төрөлхийн радиоулнар синостозын (CRUS) анхны тохиолдлын ач холбогдлыг таньж мэдэх, энэ жишээний эрт үед анхаарал хандуулах зорилготой юм.

Түлхүүр үг: Хүннү, Радиоулнар синостоз, төрөлхийн радиоулнар синостоз, палеопатологи, Монгол, Хүннү

Introduction

One of the most crucial functional movements of the upper extremity is the forearm's rotational motion (pronation or supination). Serious problems result from congenital or post-traumatic radioulnar synostosis-related restrictions on rotation. When any two bony elements fuse, the result is called synostosis (Buikstra, 2019). Radioulnar synostosis (RUS) can develop congenitally, be part of a syndrome, be an isolated disorder, or be the result of forearm trauma. If RUS is to provide genetic hints regarding archaeological samples, it must be possible to distinguish between congenital (CRUS) and post-traumatic forms of RUS based on osteological characteristics (Antón & Polidoro, 2000). Other skeletal abnormalities associated with CRUS include congenital hip dislocation, clubfoot, familial fibular and tibial synostosis, syndactyly, polydactyly, abnormalities of the knees, including nail-patella syndrome, and pre-axial elements of the hands (Buikstra, 2019; Teitelbaum & Verano, 2015; Wolin et al., 2020).

Materials and Methods

The Ulaanbulag site is situated on a plateau on the southern slope of a high mountain with forests behind it and rocks in front, more than 30 km south of the Russian border and 24 km northeast of the town of Yeröö soum in Selenge province (Fig. 1). There is a total of 122 human burials at Ulaanbulag dating from the Bronze Age to the 14th century CE. In 2022, the

Mongolia-Japan joint expedition excavated three burials dating from the Xiongnu period (3rd century BCE – 1st century CE). A well-preserved subadult male human skeleton was found in the first burial pit (No. 43), 205 cm below the surface. The individual was interred in a wooden coffin with a stone enclosure. The subadult skeleton was looted by robbers and human bones were scattered over the coffin (Fig. 2), but the lower body was intact, and based on that, the skeleton was determined to have been buried in an extended position. Four bone projectile points and fragments of pottery sherds were found. Inhumation with the skeleton on its side in an extended position was the common burial practice during the Xiongnu period.

Age estimation for this juvenile male individual was made according to the state of tooth formation eruption and epiphyseal fusion (Scheuer & Black, 2000; Schour & Massler, 1941). Age estimation was based on postcranial fusion (Scheuer & Black, 2000) and dental eruption and development (Buikstra & Ubelaker, 1994). The individual's cranial and postcranial skeleton was examined for anomalies such as developmental defects and for evidence of pathological conditions, including cribra orbitalia, joint disease, abnormal size or shape of bones, bone addition or loss, and healed and unhealed trauma. In addition to dental wear, teeth were assessed for carious lesions, enamel hypoplasias, calculus, and abscesses. Radiography was not available at the time of observation (Nikita, 2017).

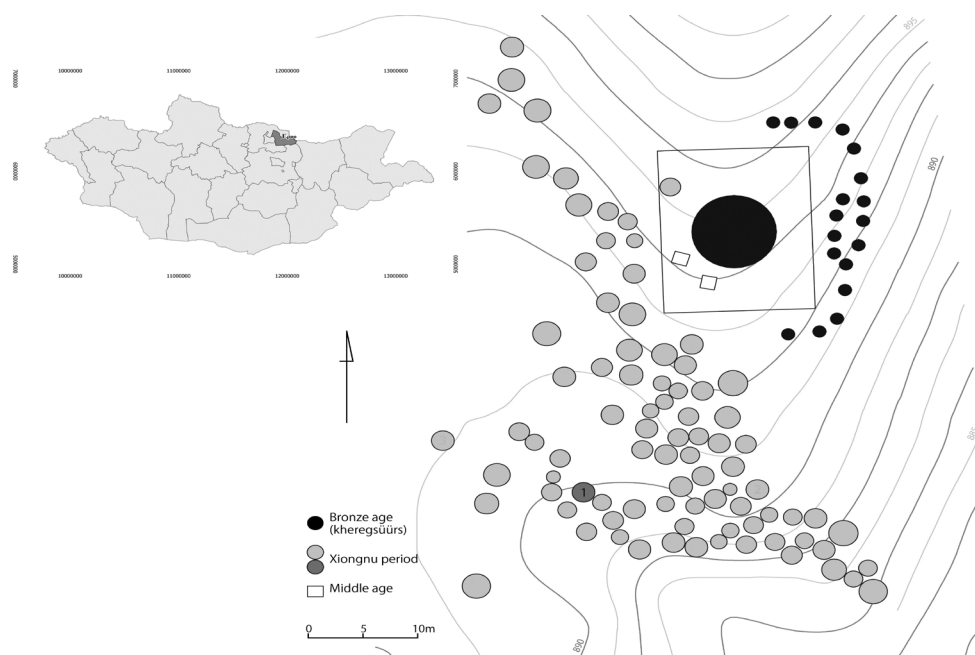


Figure 1. Location of the Individual 1 burial, Ulaanbulag, Yeröö soum, Selenge province, Mongolia



Figure 2. Plan view of Individual 1 skeleton in burial pit.

Results

The presence of radioulnar synostosis was recognized during examination of the skeleton that is complete with the exception of some of the bones of the hands and feet (Fig. 2). The cranium was relatively gracile with a sharp supraorbital margin because the individual had not yet reached adulthood. However, biological sex was determined to be male because the subpubic angle and greater sciatic notch (Phase 4) were narrow and coexistent with completely ossified acetabular epiphyses, indicating mostly matured coxal bones. The root apical foramen was half-closed in the third molar. Therefore, the dental age was 19.1 years based on the data of Smith (Smith, 1991), although it should be noted that the timing of the formation in the third molar is subject to great individual variation. Secondly, unfused epiphyses were dominated by areas that generally close in the late teens and 20s, whereas many of the areas that are supposed to begin closing in an individual's early teens had already fused. Based on these observations, the age at death is estimated to have been 16-20 years in terms of both dental and skeletal age.

Our observations noted that between the supinator and pronator rotations, the right radius and right ulna were united at their proximal ends (Fig. 3). The proximal radioulnar joint and the radial and ulnar tuberosities were fused together. The radius on the affected side was twisted medially from the middle of the diaphysis to the distal end. In contrast, the diaphysis of the healthy left side was externally curled (Fig. 3), and the ulna on the damaged side was significantly thinner than on the healthy side.

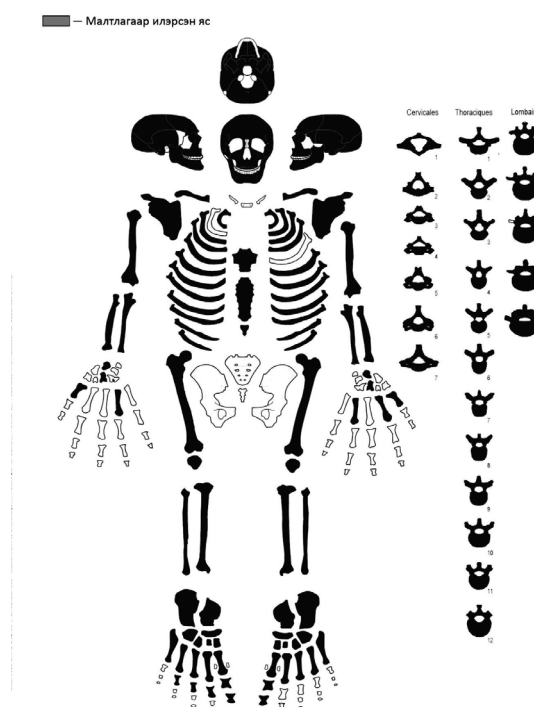


Figure 3. Skeletal inventory for Ulaanbulag Individual 1.

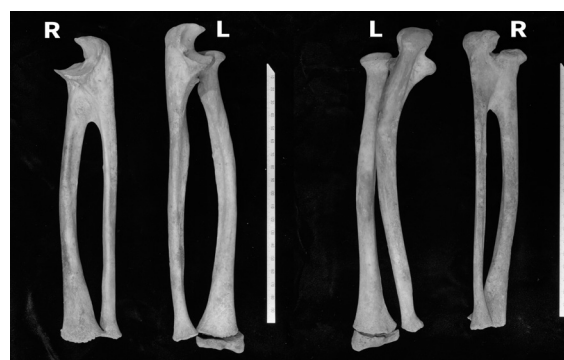


Figure 4. Ulnae and radii of Ulaanbulag Individual 1. (Left-Right: Anterior and inferior views).

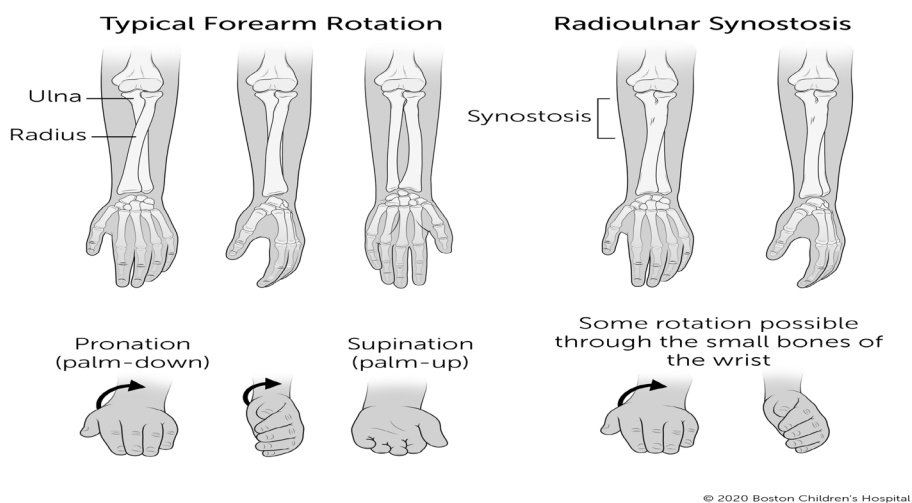


Figure 5. Differences in rotation capabilities with radioulnar synostosis. (Copyright by Boston Children's Hospital 2020).

Two shallow grooves were observed on the labial surface of the crown of the maxillary central incisor, which could indicate a type of enamel hypoplasia. Dental enamel hypoplasia is a developmental defect caused by physiological stress during tooth development (D'Anastasio et al., 2013; Guatelli-Steinberg et al., 2013). Studies of such developmental defects in populations can give insights into patterns of dietary and disease stress in prehistoric groups. Faint “comb marks” were seen on the surface of the femoral and tibial diaphysis and are interpreted as evidence of mostly healed mild periostitis (an inflammation of the periosteum caused by trauma or infection which

can be acute or chronic) (White et al., 2012). The fifth lumbar vertebral arch was separated from the body on both sides of the lamina. Small osteophyte is seen in part of the separation and along the margin of the left superior articular process. These symptoms cumulatively lead to a diagnosis of lumbar spondylolysis. The fracture through the pars interarticularis of (usually) the fifth lumbar vertebra (spondylolysis), is classified as a type of stress fracture (Buikstra, 2019). The impressions for the costoclavicular ligament were remarkably developed for a late teenager, and was deeply depressed, especially on the right side (Fig. 5).

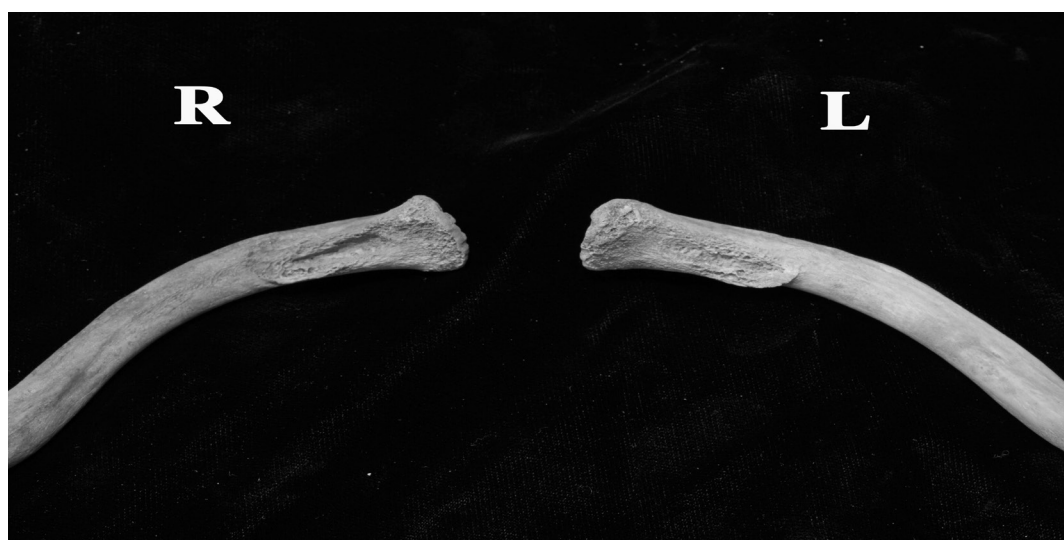

Figure 6. Inferior view of clavicles, Ulaanbulag Individual 1.

Differential Diagnoses

A review of clinical and paleopathological literature was conducted to assess differential diagnoses for the conjoined elements. The authors considered three main diagnoses to account for the observed abnormalities: spondyloarthropathy, post-traumatic synostosis, and CRUS.

Spondyloarthropathy

Spondyloarthropathy is a constellation of arthritic conditions, including ankylosing spondylitis, reactive arthropathy, psoriatic arthropathy, and enteropathic arthropathy. Rothschild and Martin (2006:49) define spondyloarthropathy as the "...tendency to reactive bone formation, ossification at sites of tendon, ligament, or capsule insertion, asymmetrical pauciarticular peripheral joint erosions and fusions, and axial (e.g. spine and sacroiliac) joint disease." They are associated with the HLA-B27 antigen, asymmetric, and typically affect the joints of the spinal column, knees, hands, and feet (Buikstra, 2019; Ortner, 2003). Ligaments may ossify, which results in the fusion of the ribs to the vertebrae. Additionally, other major joints such as the knee and elbow may be affected (Aufderheide, Rodríguez-Martín, & Langsjoen, 1998). There is no macroscopic evidence of these degenerative changes; thus, a diagnosis of spondyloarthropathy is not supported.

Post-traumatic Radioulnar Synostosis

Post-traumatic RUS results from the ossification of a hematoma or the interosseous membrane following a fracture, dislocation, or other traumatic event (Buikstra & Ubelaker, 1994; Ortner, 2003). Typically unilateral, this complication can severely limit movement and cause pain (Nikitovic et al., 2012; Oka et al., 2006). Osteologically, post-traumatic RUS is identified by evidence of a fracture, bone remodeling and healing, and secondary changes such as osteoarthritis – none of which were observed in Ulaanbulag Individual 1.

Congenital Radioulnar Synostosis

Congenital radioulnar synostosis (CRUS) occurs when the shared perichondrium of the radius and ulna fail to properly segment and subsequent endochondral ossification fuses the two elements in the position of the arms in utero – ranging from neutral to pronated (Taneja and Ramachandran, 2015). CRUS lacks the presence of bone remodeling, sclerotic bone lesions, and ossification of connective tissues. In Ulaanbulag Individual 1, there was no evidence of (a) bone remodeling, (b) ossification of connective tissues, (c) fracture, and/or (d) periosteal reaction (Fig 6). A lack of remodeling supports the hypothesis that the pathological changes observed in Individual 1 are indicative of CRUS and the observed bone changes cannot be associated with any other conditions at this time.

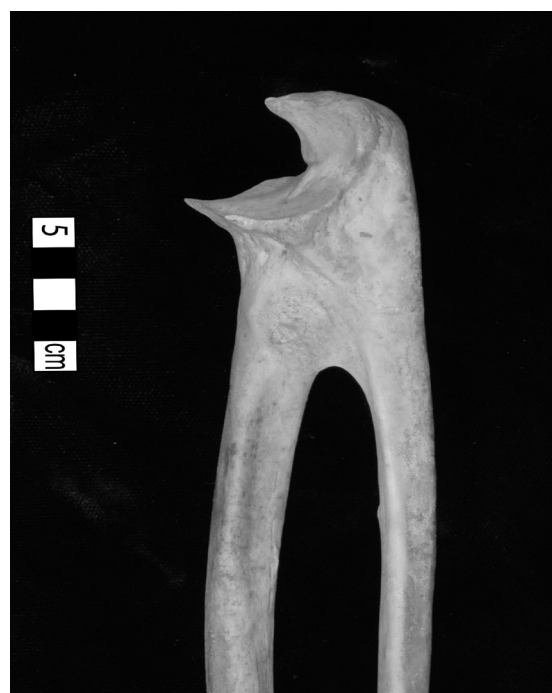

Figure 7. Congenital radioulnar synostosis, medial view, Ulaanbulag Individual 1.

Discussion and Conclusions

Limited use of the right arm could have affected the ability to perform age/gender-specific tasks and may have required greater dependency compared to other members of the social group. Although mortuary practices reflect various aspects of social identity, the burial of the Ulaanbulag subadult follows the mortuary practices of other burials from this period, suggesting that potential physical disability did not affect interment procedures for this individual. Also, the development of a right-sided impression of the costoclavicular ligament suggests that although Ulaanbulag Individual 1 was impaired regarding pronation-supination movement, he was able to move his upper extremities in a way that compensated for this limitation.

Based on our other observations, this individual suffered some stress during his childhood. Evidence of healed periostitis suggests that he experienced an acute infection or that the radioulnar synostosis abnormality could have led to this condition. Moreover, enamel hypoplasia may have been caused by dietary and/or disease stress. Perhaps Individual 1's disability didn't negatively impact his social status, but it certainly affected his lifestyle and health.

Congenital radioulnar synostosis is a rare developmental abnormality that has been reported infrequently in the medical and paleopathological literature. Only fifteen cases of CRUS have thus far been reported worldwide from archaeological contexts (Wolin

et al., 2020). Only 350 cases have been identified worldwide (Okotcha et al., 2022). The case presented here documents the first example of CRUS from an archaeological context in Mongolia and prompts us to remain alert for further cases of congenital osseous fusion in the country.

Acknowledgements

The authors are grateful to the Mongolia-Japan joint “Clarifying state, social system, and the relationship between the Xiongnu and the Han Dynasty Based on Archaeological Findings” field research team. This work was supported by JSPS KAKENHI Grant number JP23H00695.

References cited

Antón, S. C. & Polidoro, G. M. (2000). Pre-historic radio-ulnar synostosis: implications for function. In *International Journal of Osteoarchaeology*, Volume 10, Issue 3, pp. 189-197. [https://doi.org/10.1002/1099-1212\(200005/06\)10:3<189::AID-OA521>3.0.CO;2-G](https://doi.org/10.1002/1099-1212(200005/06)10:3<189::AID-OA521>3.0.CO;2-G)

Buikstra, J. E. (2019). Ortner’s identification of pathological conditions in human skeletal remains. In *Ortner’s Identification of Pathological Conditions in Human Skeletal Remains*. Elsevier. <https://doi.org/10.1016/B978-0-12-809738-0.00001-6>

Buikstra, J. E. & Douglas H. Ubelaker. (1994). Standards for data collection from human skeletal remains. *Proceedings of a Seminar at the Field Museum of Natural History*.

D’Anastasio, R., Cesana, D. T., Viciano, J., Sciubba, M., Nibaruta, P., & Capasso, L. (2013). The possible correlation between dental enamel hypoplasia and a historic natural disaster in the Roman population of Herculaneum (79 AD - Central Italy). *Anthropologischer Anzeiger*, 70(4), 369–383. <https://doi.org/10.1127/0003-5548/2013/0312>

Guatelli-Steinberg, D., Buzhilova, A. P., & Trinkaus, E. (2013). Developmental stress and survival among the mid-upper Paleolithic Sunghir children: dental enamel hypoplasias of Sunghir 2 and 3. *International Journal of Osteoarchaeology*, 23(4), 421–431. <https://doi.org/10.1002/oa.1263>

Nikita, E. (2017). *Osteoarchaeology: A Guide to the Macroscopic Study of Human Skeletal Remains*. Academic Press.

Nikitovic, D., Janković, I., & Mihelić, S. (2012). Juvenile elbow dislocation from the prehistoric site of Josipovac-Gravinjak, Croatia. *International Journal of Paleopathology*, 2(1), 36–41. <https://doi.org/10.1016/j.ijpp.2012.06.001>

Oka, K., Doi, K., Suzuki, K., Murase, T., Goto, A., Yoshikawa, H., Sugamoto, K., & Moritomo, H. (2006). In vivo three-dimensional motion analysis of the forearm with radioulnar synostosis treated by the Kanaya procedure. *Journal of Orthopaedic Research*, 24(5), 1028–1035. <https://doi.org/10.1002/jor.20136>

Okotcha E, Goldfinger M, Bell T, Griffin A. A rare case of congenital radioulnar synostosis. *Consultant*. 2022;62(6); e14-e16. doi:10.25270/con.2021.11.00004

Ortner, D. J. (2003). *Identification of Pathological Conditions in Human Skeletal Remains (Second Ed.)*. Elsevier Inc. <https://doi.org/10.1016/B978-0-12-809738-0.00017-X>

Scheuer, L. & S. Black. (2000). *The Development of Juvenile Osteology (Louise Scheuer & Sue Black, Eds.)*. Academic Press.

Schour, I., & Massler, M. (1941). *The Development of the Human Dentition* (pp. 1153–1160).

Smith, B. H. (1991). Standards of human tooth formation and dental age assessment. In Marc A. Kelley & Clark Spencer Larsen (Eds.), *Advances in Dental Anthropology* (pp. 143–168). Wiley-Liss Inc.

Taneja, T., Ramachandran, M., 2015. Congenital radioulnar synostosis. In: D. R. Laub Jr. (Ed.), *Congenital Anomalies of the Upper Extremity*. Springer, Boston, pp. 117–121

Titelbaum, A. R., & Verano, J. W. (2015). A case of congenital radioulnar synostosis from Prehispanic Peru. *International Journal of Osteoarchaeology*, 25(6), 968–975. <https://doi.org/10.1002/oa.2353>

White, T. D., Black, M. T., & Folkens, P. A. (2012). *Human Osteology (3rd ed.)*. Academic Press.

Wolin, D., Young, M., & Lopez Aldave, N. (2020). Bilateral congenital radioulnar synostosis in an Early Horizon subadult burial from the site of Atalla, Peru. *International Journal of Paleopathology*, 28, 1–5. <https://doi.org/10.1016/j.ijpp.2019.11.004>

Received: 30 September 2023

Revised: 17 November 2023

Accepted: 01 December 2023



Open Access This is an open access article distributed in accordance with the Creative Commons Attribution Non Commercial (CC BY-NC 4.0) license, which permits others to distribute, remix, adapt, build upon this work non-commercially, and license their derivative works on different terms, provided the original work is properly cited, appropriate credit is given, any changes made indicated, and the use is non-commercial. See: <http://creativecommons.org/licenses/by-nc/4.0/>.