

IOTA model for surgical management of ovarian tumors: A case from Mongolia

Ureltsetseg Batdelger^{1*}, Sergelen Purev², Batbold Tseelejav², Bolortuya Batbayar², Michidmaa Narangerel², Beulah Jambaldorj², Byambajargal Sarantuya², Odonchimeg Dagvajantsan², Gulgaim Kabyenkye², Shiilegpagam Sanligsuren², Tugsbayar Nanzaddorj², Nyamtsetseg Buyankhishig²

¹ Department of Management, School of Economics and Business, Mongolian University of Life Sciences, Ulaanbaatar, Mongolia

² Department of Obstetrics and Gynecology, AMH, Ulaanbaatar, Mongolia

KEYWORDS

Ovarian Tumor, Fertility Preservation, Frozen Section, Borderline Tumor, Twin Pregnancy

Received: 2025.9.22

Revised: 2025.11.20

Accepted: 2026.01.10

Published: 2026.01.28

Copyright: © Author(s), 2026 CC BY-NC 4.0 - <https://creativecommons.org/licenses/by-nc/>

ABSTRACT: Preoperative assessment of ovarian pathology is essential to ensure that patients with ovarian cancer receive appropriate treatment and achieve optimal clinical outcomes. The International Ovarian Tumor Analysis (IOTA) collaboration has developed standardized ultrasound-based methods for characterizing adnexal lesions. Complementing imaging, intraoperative frozen section histological analysis a rapid diagnostic technique introduced in 1905 provides results within 15–30 minutes and plays a pivotal role in surgical decision-making, particularly for reproductive-age women requiring fertility-preserving interventions. This approach demonstrates diagnostic accuracy of 94%, with 75% sensitivity and 100% specificity for ovarian tumors. Although ovarian cancer is relatively rare among women of reproductive age, it frequently presents at advanced stages, often necessitating radical surgery. Integrating preoperative and intraoperative diagnostic strategies offers a comprehensive framework for individualized surgical management, optimizing outcomes while preserving fertility where feasible.

Background: This report details a case of successful twin pregnancy following fertility sparing surgery guided by frozen section histology in a patient with bilateral mucinous borderline ovarian tumors. Fertility preserving approaches are increasingly viable and ethically significant for younger patients desiring future pregnancy. Here, we present a 38-year-old woman diagnosed with high grade serous ovarian carcinoma who underwent fertility sparing surgery guided by intraoperative frozen section histology and subsequently conceived and delivered healthy twins.

Methods: A 38-year-old woman presented with acute left lower abdominal pain. Her obstetric history was gravida 3, para 2, including one miscarriage, with no conception over the past 10 years. Imaging revealed a multiloculated 13.6 cm left ovarian mass with vascularity and a honeycomb appearance. Serum CA-125 level was 60 U/mL. Laparoscopic surgery included left salpingo oophorectomy, right ovarian wedge biopsy, omental biopsy, and peritoneal cytology. Intraoperative frozen section analysis revealed a

* Corresponding author: Department of Management, School of Economics and Business, Mongolian University of Life Sciences, Ulaanbaatar, Mongolia.

Email: Ureltsetseg.b@mul.edu.mn, ORCID: <https://orcid.org/0009-0009-9234-7354>

left mucinous borderline tumor with intraepithelial carcinoma and mucinous borderline changes on the right. The uterus and right adnexa were preserved.

Results: Final histology confirmed Stage IB mucinous borderline carcinoma of the left ovary and a right borderline tumor. The patient completed six cycles of chemotherapy with cyclophosphamide and cisplatin. She remained disease-free for two years and spontaneously conceived three years postoperatively. On 7 March 2025, she delivered healthy twins via emergency caesarean section at 36–37 weeks due to pre-eclampsia, twin gestation, and a history of uterine scarring.

Conclusion: Intra operative frozen section histology enables rapid and reliable assessment of ovarian malignancy, allowing informed fertility preserving surgical decisions without compromising oncological safety. This case illustrates successful application in bilateral mucinous borderline ovarian tumors, resulting in spontaneous conception and healthy twin delivery. Fertility sparing surgery guided by frozen section histology can be safely implemented in tertiary care hospitals in Mongolia, highlighting its potential to improve reproductive and oncological outcomes in young women with early stage ovarian tumors and supporting the development of national clinical protocols.

INTRODUCTION

Accurate preoperative differentiation between benign and malignant adnexal masses is a cornerstone for optimal patient management. Although most women presenting with an adnexal mass do not have ovarian cancer, correctly identifying benign lesions is essential to prevent unnecessary interventions, reduce healthcare costs, and minimize patient morbidity.^{1,2} Conversely, timely detection of malignant lesions enables prompt treatment and appropriate surgical staging at specialized gynecologic oncology centers, which is critical for achieving favorable oncological outcomes.^{3,4} Various diagnostic tools have been developed to enhance preoperative assessment of ovarian masses. These include ultrasonography based scoring systems focusing on morphological features, serum biomarkers such as CA-125 integrated into the Risk of Malignancy Index (RMI), and more advanced computational models including logistic regression, neural networks, and other machine learning algorithms.^{4,5} Among these, the RMI remains the most widely applied globally, although its predictive performance is heavily influenced by serum CA-125 levels. Systematic reviews confirm that RMI provides reliable triage for referral to tertiary oncology units.^{5,6}

Guidelines from professional bodies such as the American College of Obstetricians and Gynecologists (ACOG) recommend biomarker-based assessment for determining referral to gynecologic oncology centers.⁷ However, these protocols are less effective in detecting early-stage ovarian cancer and in premenopausal women.⁸ Alternative biomarkers, such as the OVA-1 panel, can improve sensitivity but are associated with high false positive rates, limiting clinical utility.^{9,10} Numerous other predictive models have been proposed to enhance preoperative diagnostic accuracy, yet most failed to maintain their performance during external validation. Contributing factors include limited sample sizes, single-center development, tumor heterogeneity, inconsistent ultrasound terminology, and variability in histopathological reporting.^{11,12} To overcome these limitations and provide a reproducible, evidence-based framework applicable across diverse clinical settings, the International Ovarian Tumor Analysis (IOTA) collaboration was established. Standardized IOTA models including Logistic Regression models (LR1 and LR2) and the IOTA Simple Rules demonstrate high diagnostic accuracy and consistency, supporting preoperative risk stratification and informed surgical decision making.^{13,14}

Ovarian Cancer: Ovarian cancer is a malignant neoplasm originating from ovarian tissues, which are responsible for oocyte production and hormone synthesis. Histopathologically, ovarian tumors are classified into epithelial ovarian carcinoma, germ cell tumors, and sex cord-stromal tumors. Epithelial ovarian carcinoma accounts for approximately 90% of cases and includes serous, mucinous, endometrioid, and clear cell subtypes. Although germ cell and sex cord-stromal tumors are less common, they remain clinically significant, particularly in younger women.^{15,16}

Fertility-Sparing Surgery (FSS) in Ovarian Cancer: Historically, early-stage ovarian cancer was managed with radical surgery, including bilateral salpingo oophorectomy and hysterectomy. Fertility sparing surgery (FSS) has emerged as a feasible alternative for women desiring future fertility. This strategy aims to remove malignant tissue while preserving reproductive organs and is particularly relevant for young women diagnosed with early stage disease.¹⁷⁻¹⁹

International Ovarian Tumor Analysis (IOTA) and Risk Stratification: The IOTA group has developed standardized preoperative risk assessment models for adnexal masses, including the Risk of Malignancy Index (RMI), Logistic Regression models (LR1 and LR2), and the Simple Rules. These tools

integrate clinical, ultrasound, and biomarker data to stratify malignancy risk and guide surgical planning, including considerations for fertility sparing surgery.²⁰

Global Practices and Evidence-Based Guidelines:

In countries with advanced healthcare systems such as Japan, South Korea, France, Italy, and Germany—IOTA models combined with intraoperative frozen section histology have become standard practice. These approaches improve oncological outcomes and support fertility preservation by enabling accurate intraoperative assessment of malignancy, thereby facilitating the safe implementation of FSS.²¹

Fertility Preservation in Mongolia: In Mongolia, the application of IOTA models and fertility preserving strategies remains underreported. This case highlights the first documented use of IOTA in a specialized national hospital, demonstrating its potential to preserve fertility and achieve successful childbirth. Integrating evidence-based protocols such as those developed by IOTA into clinical practice could enhance patient outcomes and align local practices with international standards in ovarian cancer management.²²

Literature Review and Conceptual Framework:

Accurate preoperative differentiation between benign and malignant adnexal masses is critical for guiding clinical management and optimizing patient outcomes. The International Ovarian Tumor Analysis (IOTA) collaboration has developed standardized diagnostic models, including the Logistic Regression models (LR1 and LR2) and the Simple Rules (SR). These tools integrate clinical, ultrasound, and biomarker data to stratify malignancy risk, thereby guiding surgical decision-making, including the consideration of fertility-sparing surgery.²² The diagnostic performance of these models has been validated by several case studies across Europe. Research from multiple European centers has demonstrated that the LR1 and LR2 models achieve high diagnostic accuracy in distinguishing benign from malignant ovarian tumors, with LR2 exhibiting slightly higher sensitivity and specificity than LR1.²³ The IOTA Simple Rules have also been extensively validated, showing a sensitivity of approximately 90% and a specificity of 93%; this strong performance supports their routine use for preoperative risk stratification in European

gynecologic oncology practice. Despite these strengths, some limitations exist. The models are applicable in only 80–85% of cases, which highlights the need for adjunctive diagnostic assessment when the rules yield an inconclusive result.

In Asia, the application of IOTA models has similarly demonstrated promising results. A prospective study in India reported that the Simple Rules were applicable in 65 out of 70 patients, achieving a sensitivity of 90.9% and a specificity of 88.4% for ovarian tumor classification.²⁴ In China, combining the Simple Rules with serum CA125 and the O-RADS classification improved diagnostic accuracy, resulting in a sensitivity of 94.4% and an area under the curve (AUC) of 0.831. These findings suggest that IOTA models are adaptable across diverse healthcare settings, although local training and standardization are crucial to maintain diagnostic reliability.²⁵ The conceptual framework for IOTA model implementation centers on four key components: standardized ultrasound imaging assessment, biomarker integration, risk stratification, and clinical decision making. Ultrasound assessment using the Simple Rules identifies morphological features predictive of malignancy, while the LR1 and LR2 models incorporate additional clinical and biomarker data such as serum CA125 to refine risk estimates. These risk scores then inform surgical planning, including the consideration of fertility sparing procedures, and guide patient counseling regarding optimal management strategies. In summary, international case studies demonstrate that IOTA models, when properly implemented, enhance preoperative diagnostic accuracy, improve oncological outcomes, and support fertility preserving interventions. Comparative evidence from Europe and Asia highlights that although the models perform consistently across diverse populations, integration with biomarkers and training in standardized ultrasound evaluation are essential for maximizing their clinical utility. This evidence based framework underscores the value of IOTA models in preoperative assessment and provides a foundation for their application in emerging clinical settings, including Mongolia. The integration of such protocols could align local practices with global standards in ovarian cancer management.

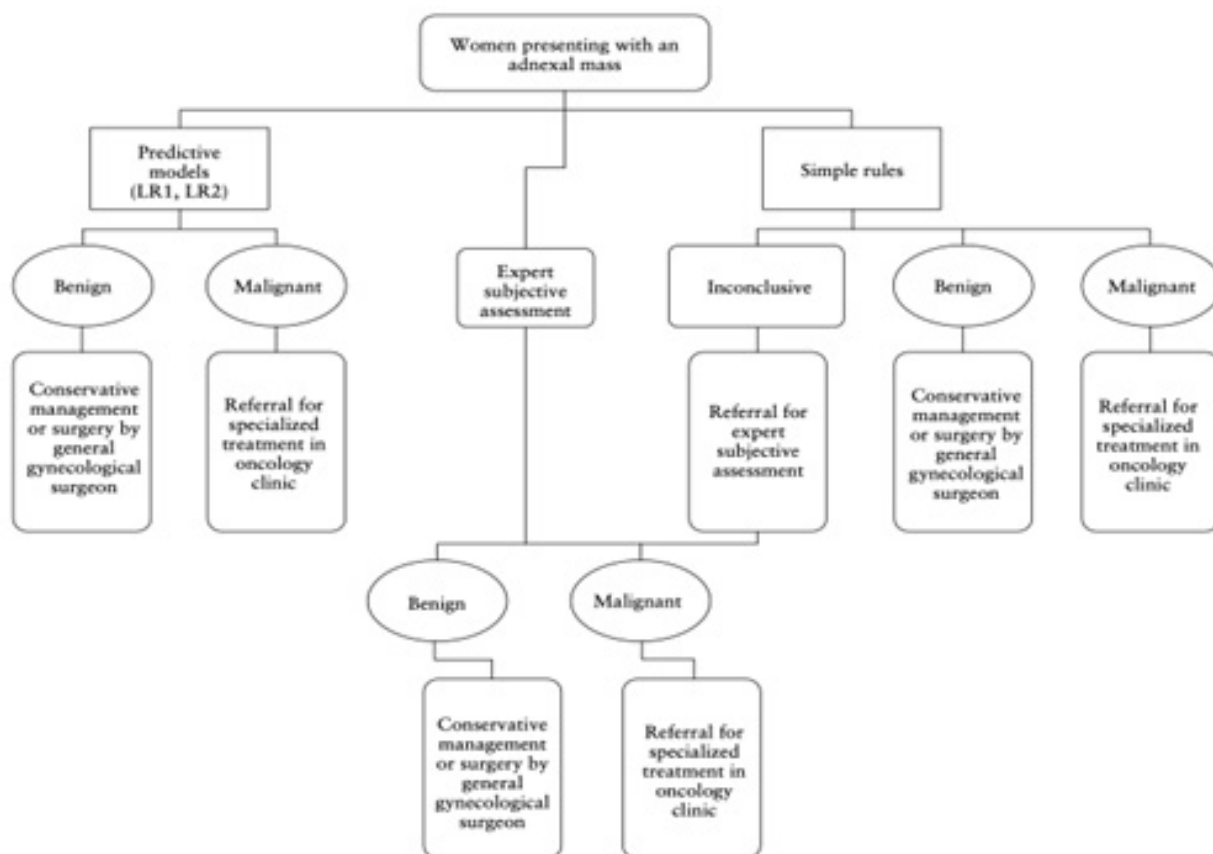


Figure 1. International Ovarian Tumor Analysis (IOTA) framework.12

Case Study Methods:

Patient Presentation and Clinical History: A 38 year old woman presented with acute left lower abdominal pain. Her obstetric history was gravida 3, para 2, with one miscarriage and a 10 year history of infertility. She had no significant comorbidities or prior gynecologic surgeries. Physical examination revealed a palpable mass in the left lower abdominal quadrant. Transvaginal ultrasonography identified a 13.6 cm multiloculated left ovarian mass with internal vascularity and a honeycomb pattern. The right ovary was unremarkable. Serum CA-125 was elevated at 60 U/mL; other laboratory values were within normal limits. **Surgical Intervention and Intraoperative Assessment:** Laparoscopic surgery was performed, which included a left salpingo-oophorectomy, a wedge biopsy of the right ovary, an omental biopsy, and peritoneal cytology. Intraoperative frozen section analysis revealed a mucinous borderline tumor with intraepithelial carcinoma on the left ovary and mucinous borderline changes on the right. To preserve fertility, the uterus and right adnexa were preserved. Final histology confirmed a Stage IB mucinous borderline carcinoma of the left ovary and a borderline tumor on the right. **Postoperative Course and Outcome:**

The patient subsequently completed six cycles of adjuvant chemotherapy with cyclophosphamide and cisplatin. She remained disease free throughout two years of surveillance. Three years postoperatively, the patient conceived spontaneously and delivered healthy twins via emergency cesarean section at 36–37 weeks of gestation due to pre-eclampsia and a history of uterine scarring. Informed consent was obtained from the patient for both treatment and publication of this case. All study protocols adhered to the principles of the Declaration of Helsinki and were approved by the institutional ethical review board.

Case Report

Mucinous ovarian tumors represent a subset of epithelial ovarian neoplasms that, when detected at an early stage, may allow for fertility preserving surgical management. Careful preoperative assessment, intraoperative decision making, and postoperative follow-up are critical for balancing oncologic safety with reproductive outcomes. This case report describes a patient with Stage IB mucinous ovarian carcinoma who was managed with fertility-sparing surgery and subsequently achieved a successful twin pregnancy.

Case Presentation

Diagnostic Assessment: Pelvic ultrasound demonstrated a multilocular mass measuring 13.6 × 10 × 9.7 cm with honeycomb-like septations and increased vascularity. Laboratory evaluation revealed an elevated CA-125 level (60 U/mL) and an elevated Inhibin B level (58.24 pg/mL); lactate dehydrogenase (LDH, 300 U/L) and alpha-fetoprotein (AFP, 4.9 U/mL) were within normal limits. Endoscopy and chest radiography showed no evidence of metastasis.

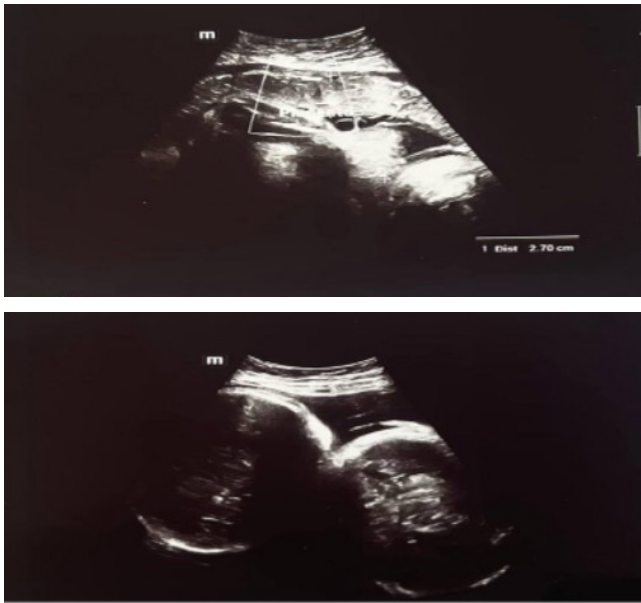


Figure 2. Ultrasound image

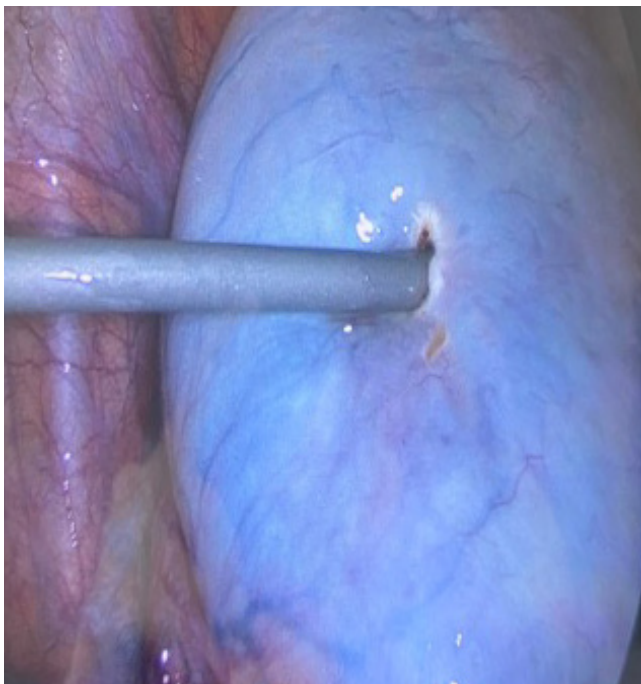


Figure 3. The surgical procedure

Preoperative risk assessment using the International Ovarian Tumor Analysis (IOTA) criteria indicated a high malignant potential. The IOTA Simple Rules identified multilocularity, solid components, and

increased vascularity as suspicious features, while the ADNEX model estimated a high probability of a borderline or malignant ovarian tumor. The patient conceived spontaneously three years after surgery. Prenatal care commenced at 6–7 weeks of gestation, and she underwent six routine antenatal assessments. Early pregnancy nausea persisted until the fourth month. At 27–28 weeks, she developed mild preterm labor with a risk of premature birth; her history of two prior cesarean sections and uterine scarring was noted. At 34–35 weeks, she experienced elevated blood pressure, and the previously noted uterine scarring remained a consideration; twin gestation (dichorionic, two placentas, two amniotic sacs) was confirmed. At 36–37 weeks, mild preterm contractions recurred. Throughout the pregnancy, her blood pressure remained stable (~120/80 mmHg), and she gained 15 kg. Chronic comorbidities included mild cardiac symptoms, recurrent pharyngitis, and untreated dental caries. Medications included vitamin D (4000 IU), aspirin (150 mg), calcium D3, methyldopa (250 mg), and supplemental oxygen as needed.

- On 5 March 2025, she presented with abdominal tightening and headache; her blood pressure was 131/88 mmHg (right arm) and 129/88 mmHg (left arm), and urinalysis revealed proteinuria (100 mg/dL). She was admitted for a planned cesarean delivery at 36–37 weeks due to mild preterm contractions, prior uterine surgery, and twin gestation.
- **Delivery and Outcome:**
First twin: 08:54, female, 2800 g, 48 cm, Apgar 7/8
Second twin: 08:56, male, 3050 g, 49 cm, Apgar 7/8
- **Placental Findings:** The placentas were intact with a combined weight of 610 g and a thickness of 1.9 cm; the diameter measured 18 × 21 cm. The umbilical cord had a central insertion and was 50 cm in length. The estimated blood loss during surgery was 500 mL. Postoperatively, both the mother and neonates remained stable. The patient was monitored in the postpartum ward for 72 hours and was subsequently discharged in good condition.

Final Histology:

Left ovary: Stage Ib mucinous ovarian carcinoma

Right ovary: Borderline mucinous tumor

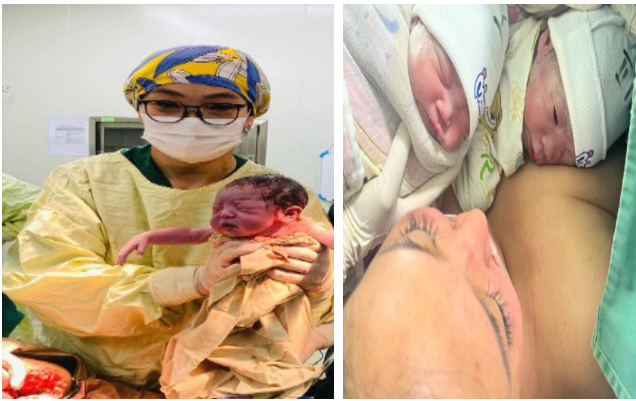

Figure 4. Postoperatively, two viable twins were delivered without complications

Discussion: This case demonstrates the role of IOTA-based evaluation in guiding intraoperative decision-making and enabling fertility-preserving surgery in early-stage ovarian cancer. International studies confirm that IOTA enhances diagnostic accuracy, reduces overtreatment, and supports tailored surgical strategies.^{26,27} In European cohorts, the use of IOTA combined with frozen section histology achieved disease-free survival (DFS) rates of >95% in Stage I borderline ovarian tumours, outcomes comparable to standard radical surgery, while preserving reproductive potential.^{28,29} Similarly, Asian studies show improved reproductive outcomes and reduced recurrence following fertility-sparing surgery (FSS) when guided by IOTA.^{30,31} The present case is the first report from Mongolia demonstrating a successful pregnancy and live twin birth following IOTA-guided FSS. It highlights the potential to integrate evidence-based diagnostic models into national oncology practice, ensuring both oncological safety and reproductive health.

Conclusion: The findings of this case study highlight the critical role of the IOTA model in enhancing diagnostic accuracy and guiding surgical decision-making for ovarian tumours. As demonstrated in this Mongolian patient, IOTA-based preoperative and intraoperative assessment provided a robust framework for determining malignancy risk, which directly influenced the choice of fertility-preserving surgery (FSS). This approach not only ensured oncological safety but also safeguarded the patient's reproductive potential, ultimately resulting in a successful twin pregnancy and live birth. Globally, increasing evidence from Asian (e.g., Japan, Korea, China) and European (e.g., France, Italy, Denmark) studies underscores the clinical utility of IOTA in optimising treatment strategies for borderline and early-stage ovarian tumours. The present case aligns with these international findings, confirming that IOTA-guided FSS can achieve disease-free survival

rates comparable to traditional radical surgery while preserving fertility. The absence of recurrence in this patient during long-term follow-up further validates the oncological safety of this strategy. Importantly, this study represents one of the first documented cases in Mongolia where IOTA was integrated into the decision-making process for ovarian tumour surgery. By adapting this evidence-based model to the local clinical setting, it demonstrates the feasibility of incorporating advanced diagnostic tools into reproductive healthcare in resource-limited environments. The successful pregnancy outcome also highlights the profound impact of such approaches on the quality of life and psychosocial wellbeing of women of reproductive age. In conclusion, the integration of the IOTA model with fertility-preserving surgical techniques offers a powerful and safe clinical pathway for managing ovarian tumours in young women. This case adds to the international body of evidence, supporting the adoption of IOTA as a standard component of ovarian tumour assessment worldwide. Future research in Mongolia and other low- and middle-income countries should further evaluate the scalability, cost-effectiveness, and long-term outcomes of this strategy, thereby contributing to global improvements in women's oncological and reproductive health. In Mongolia, it is of paramount importance that fertility-sparing surgery is successfully performed and consistently supported in specialized tertiary care hospitals according to high-quality international standards, regardless of geographic location.

References

1. Alcazar JL, Guerriero S. Role of ultrasound in ovarian cancer diagnosis: IOTA studies. *Ultrasound Obstet Gynecol.* 2019;53(5):604-616. doi:10.1002/uog.20205.
2. Amant F, Moerman P, Neven P, Timmerman D, Van Limbergen E, Vergote I. Gynecologic cancer in pregnancy: guidelines of the European Society of Gynecologic Oncology. *Gynecol Oncol.* 2005;99(2):270-282. doi:10.1016/j.ygyno.2005.06.017.
3. Banerjee R, Kaye S. New strategies in the management of ovarian cancer: current perspectives. *Clin Cancer Res.* 2010;16(2):372-383. doi:10.1158/1078-0432.CCR-09-1901.
4. Boldrini R, Mancuso S. Fertility preservation in ovarian tumors: a multidisciplinary approach. *Reprod Biomed Online.* 2018;36(3):260-269. doi:10.1016/j.rbmo.2018.01.014.

5. Chen Y, Xu J, Liang X. Factors influencing conception after fertility-sparing surgery for early-stage epithelial ovarian cancer. *Fertil Steril*. 2017;108(5):855-862. doi:10.1016/j.fertnstert.2017.07.024.
6. Colombo N, Peiretti M, Garbi A, et al. ESMO–ESGO joint guidelines for ovarian cancer management. *Ann Oncol*. 2010;21(Suppl 5):v232-v239. doi:10.1093/annonc/mdq226.
7. Committee on Gynecologic Practice. Fertility preservation in women with cancer. *Obstet Gynecol*. 2019;133(6):e346-e356. doi:10.1097/AOG.0000000000003253.
8. ESHRE Guideline Group on Female Fertility Preservation. ESHRE guideline: Female fertility preservation. *Hum Reprod Open*. 2020;2020(3):hoaa052. doi:10.1093/hropen/hoaa052.
9. Epstein E, Fridman E. Fertility outcomes after ovarian cystectomy and borderline tumor management. *J Gynecol Oncol*. 2016;27(6):e54. doi:10.3802/jgo.2016.27.e54.
10. Fruscio R, Ceppi L, Fuso L. Fertility-sparing surgery for early-stage epithelial ovarian cancer: long-term oncologic and reproductive outcomes. *Gynecol Oncol*. 2016;143(3):550-556. doi:10.1016/j.ygyno.2016.08.017.
11. Gupta S, Papanikolaou E. The role of IOTA models in ovarian mass evaluation. *Ultrasound Q*. 2021;37(2):134-145. doi:10.1097/RUQ.0000000000000562.
12. Kaijser J, Testa AC, Valentin L, Bourne T, Sayasneh A, Van Holsbeke C, et al. Towards an evidence-based approach for diagnosis and management of adnexal masses: Findings of the International Ovarian Tumour Analysis (IOTA) studies. *Best Pract Res Clin Obstet Gynaecol*. 2009;23(6):725-738.
13. Kajiyama H, Shibata K, Mizuno M, et al. Fertility-sparing surgery in early-stage ovarian cancer: oncologic and reproductive outcomes. *Ann Surg Oncol*. 2011;18(8):2454-2461. doi:10.1245/s10434-011-1715-x.
14. Kasaven L, Fauvet R, Perrotin F. Recurrence risk in fertility-sparing surgery for borderline ovarian tumors. *Eur J Obstet Gynecol Reprod Biol*. 2019;236:84-90. doi:10.1016/j.ejogrb.2019.01.020.
15. Lu K, Wang R, Li H. Advanced borderline ovarian tumors: fertility-sparing surgery outcomes. *Reprod Sci*. 2017;24(7):991-998. doi:10.1177/1933719116673142.
16. Nasioudis D, Frey M, Chapman-Davis E, et al. Fertility-sparing surgery and survival in early-stage epithelial ovarian cancer. *Obstet Gynecol*. 2016;128(5):1077-1085. doi:10.1097/AOG.0000000000001694.
17. Satoh T, Ueda T, Mizuno M, et al. Reproductive outcomes after fertility-sparing surgery for epithelial ovarian cancer. *Cancer*. 2010;116(23):5629-5638. doi:10.1002/cncr.25379.
18. Schorge JO, Grigsby PW, Mutch DG. *Gynecologic oncology: principles and practice*. Philadelphia: Lippincott Williams & Wilkins; 2013.
19. Song T, Park S, Kim S. Predicting ovarian malignancy using IOTA ADNEX and Simple Rules models. *Ultrasound Med Biol*. 2018;44(11):2323-2332. doi:10.1016/j.ultrasmedbio.2018.07.014.
20. Sun C, Liu J, Wang P. Pregnancy outcomes after fertility-sparing surgery in borderline ovarian tumors. *Fertil Steril*. 2020;114(6):1267-1275. doi:10.1016/j.fertnstert.2020.08.004.
21. Tang A, Lin H. IOTA models in clinical decision-making for ovarian tumors. *Ultrasound Int Open*. 2015;1(2):E32-E39. doi:10.1055/s-0035-1555693.
22. Wang R, Chen X, Zhang L. Second fertility-sparing surgery in recurrent borderline ovarian tumors. *Int J Gynecol Cancer*. 2019;29(5):903-910. doi:10.1136/ijgc-2019-000459.
23. Watanabe K, Kikuchi K, Satoh T. Laparoscopic fertility-sparing surgery in early-stage ovarian cancer. *J Minim Invasive Gynecol*. 2012;19(6):716-721. doi:10.1016/j.jmig.2012.08.001.
24. Wright JD, Shah M, Mathew L. Fertility preservation in ovarian cancer: review and outcomes. *J Clin Oncol*. 2009;27(13):2209-2216. doi:10.1200/JCO.2008.20.8492.
25. Zhang Y, Li X, Liang H. Bilateral borderline ovarian tumors and fertility-sparing surgery. *Gynecol Oncol*. 2016;143(3):557-563. doi:10.1016/j.ygyno.2016.08.016.
26. Zorn KK, Neumann C. Fertility-sparing surgery in epithelial ovarian cancer: meta-analysis. *Ann Surg Oncol*. 2017;24(5):1326-1335. doi:10.1245/s10434-016-5687-3.

27. European Society for Medical Oncology. Ovarian cancer: ESMO clinical practice guidelines. *Ann Oncol.* 2021;32(Suppl 2):S115-S130. doi:10.1016/j.annonc.2021.02.012.
28. World Health Organization. Global health observatory data: reproductive health and fertility preservation. Geneva: WHO; 2022. Available from: <https://www.who.int/data/gho>
29. International Society of Ultrasound in Obstetrics and Gynecology. IOTA guidelines: management of adnexal masses. *Ultrasound Obstet Gynecol.* 2020;55(6):714-730. doi:10.1002/uog.22069.
30. Morice P, Camatte S, El-Guindy A. Conservative treatment of borderline ovarian tumors: a multicenter study. *Ann Oncol.* 2001;12(7):1009-1014. doi:10.1023/A:1011791727102.
31. Donnez J, Dolmans MM. Fertility preservation in women. *N Engl J Med.* 2017;377(17):1657-1665. doi:10.1056/NEJMra1614658.