

Comparative Study of Endoscopic and Conventional Septoturbinoplasty in Patients with Nasal Airway Obstruction

Munkhbaatar Purev ¹, Han Young Hoon ¹, Tsogtjargal Gombogaram ², Erdenekhuu Nansalmaa ³, Tamir Lkhagvasuren ¹, Nyamdulam Logshir ¹, Tsend-Ayush Altangerel ¹, Ganchimeg Palamdorj ¹

¹Department of Otorhinolaryngology, School of Medicine, Mongolian National University of Medical Sciences, Ulaanbaatar, Mongolia, ²Jargal ENT Clinic, Ulaanbaatar, Mongolia, ³Department of Pathophysiology, School of Medicine, National University of Medical Sciences, Ulaanbaatar, Mongolia

Submitted: August 23, 2022
Revised: September 2, 2022
Accepted: September 25, 2022

Corresponding Author

Ganchimeg Palamdorj, PhD
Department of Otorhinolaryngology,
School of Medicine, Mongolian
National University of Medical
Sciences, Ulaanbaatar 16081,
Mongolia
Tel: +976-9907-0533
E-mail: ganchimeg@mnums.edu.mn

This is an Open Access article distributed under the terms of the Creative Commons Attribution Non-Commercial License (<http://creativecommons.org/licenses/bync/4.0/>) which permits unrestricted non-commercial use, distribution, and reproduction in any medium, provided the original work is properly cited. Copyright© 2022 Mongolian National University of Medical Sciences

Objectives: The goal of our study was to perform endoscopic septoplasty with or without turbinate reduction and also to determine its postoperative subjective and objective improvements. **Methods:** This was a hospital-based pre and post clinical trial study of 63 patients with nasal septal deviation treated with endoscopic and conventional septoplasty with or without turbinoplasty from 2013 to 2016. Nasal airway patency was recorded before and 2.7 months after surgical treatment using a visual analogue scale (VAS), Glatzel mirror test and bilateral peak nasal inspiratory flow (PNIF) measure. **Results:** Endoscopic (27 patients) and conventional septoturbinoplasty (36 patients) was performed on 63 patients (40 males; 23 females) with a mean age of 35 years. The results showed a significant improvement of nasal passage condition in scales of VAS, Glatzel mirror test, and bilateral PNIF values after surgery in both groups. In both surgical techniques septoplasty with turbinate reduction showed better improvement in VAS and bilateral PNIF scores than septoplasty alone. **Conclusion:** The application of endoscopic technology has an advantage of precise visualization and is a valuable tool especially when it is used for educational reasons. Subjective and objective improvements were confirmed equally in both endoscopic and conventional groups.

Keywords: Nasal septum, Nasal obstruction, Nasal septal deviation, Endoscopy, Turbinate

Introduction

Endoscopic septoplasty was first described in 1991 by Lanza and Stammberger as an alternative to the traditional technique [1]. Two decades later, it has been accepted as a viable method of treatment of nasal septal deformities and is frequently

performed in conjunction with endoscopic submucosal resection of the inferior turbinates and sinus surgery. Owing to improved visualization, the endoscopic approach offers both technical and educational advantages over traditional septoplasty.

In case of septoplasty, it is among the three most commonly performed procedures in otolaryngology [2], and is particularly

well suited to endoscopic application.

Lanza et al [3] have used endoscopic septoplasty not only for treating symptomatic nasal obstruction but also for improving surgical access to the middle meatus as an adjunct to endoscopic sinus surgery (ESS).

When compared with standard headlight septoplasty, the endoscopic technique provides several important advantages. Visualization with the endoscope enables improved evaluation of septal deformities in the nasal valve region and is particularly helpful in diagnosis and correction of posterior septal deformities. In addition, the improved visualization permits limited, minimally invasive surgery for isolated deviations or for revision cases. Furthermore, a more natural transition between septoplasty and ESS is possible when the 2 procedures are performed jointly with the endoscope [4].

The endoscopic technique offers several advantages compared with traditional septoplasty, most notably enhanced visualization of the septal deviation. This facilitates more focused mucosal flap dissection with resection of the offending cartilage and bone, and helps not only in primary surgical cases but also in revision cases [5]. It also allows for a more natural transition when the procedure is combined with ESS. Furthermore, the endoscopic technique can facilitate teaching endeavors when used with video monitors [5].

Objective tests of nasal function should ideally be comfortable for patients, accurate, standardizable, easily done, clinically applicable, and should not affect the nasal anatomy and physiology. Such tests should also be reproducible, which is the possibility of producing consistent results when repeated independently. By completing the above criteria, the Glatzel mirror test can be used in every day clinical practice which does not require special experience, is cost effective and easy to perform. In our study we chose the Glatzel mirror test in order to confirm its clinical value whether it can be used in further everyday clinical practice to obtain a reliable objective outcome.

Zwaardemaker first described the technique, which Glatzel later popularized. It has been in use for over 100 years. This method for objectively evaluating nasal respiratory function consists of observing the condensation of exhaled air on a cold metal surface. The clinical examiner may obtain a momentary assessment of nasal patency by comparing the condensation area of each nasal nostril. This technique has helped understand nasal cycles, and has been used in monitoring patients after

nasal surgery. However, few studies validating the data obtained by using the Glatzel mirror test [6, 7].

As objective outcome evaluation we also used peak nasal inspiratory flow meter (PNIF) like our other series of studies [8], because it is inexpensive and measurements are quick and easy to perform [9]. Most importantly, PNIF's sensitivity (0.66 vs 0.77), specificity (0.8 vs 0.8) and diagnostic accuracy (0.72 vs 0.79) are almost the same with rhinomanometry [10], which is regarded as the main standard in objective measurements of nasal obstruction.

One of the main reasons we wish to document our results, is that till now none of the English written international scientific journals have published results of endoscopic septoplasty with or without turbinate reduction in Central Asian people especially in Mongolians, therefore previous notable publications related to this endoscopic technique were created mainly from the USA [4, 11] and from other European countries [12]. Another reason we wish to report our results is that we used cost effective subjective (VAS) and objective clinical methods (PNIF and the Glatzel mirror test pre and postoperatively in order to validate both results of endoscopic and conventional technique. We consider these methods are convenient to use in any ENT clinics without any special limitations instead of using expensive high technology which many clinics could not afford.

The first goal of our study was to perform the endoscopic septoplasty with or without turbinate reduction and also to determine its postoperative subjective and objective outcomes.

The second goal of our study was to determine the subjective and objective outcome differences between endoscopic and conventional groups pre- and postoperatively.

Materials and Methods

Study design and patient recruitment

This hospital-based pre and post clinical trial study performed among 63 patients (40 men and 23 women between 16 – 64-years-old) with nasal septal deviation treated with nasal septoplasty with or without turbinoplasty at University Central Hospital of Mongolian National University of Medical Sciences from September 2013 to January 2016.

Exclusion criteria were patients under the age of 16 years, inability to give informed consent, incomplete data and those undergoing concomitant procedures.

Endoscopic septoplasty technique

The septoplasty is performed under general anesthesia. At first the nasal mucosa is decongested by topical 1:100,000 epinephrine soaked cotton pledgets. Under endoscopic visualization with a 0° endoscope, the following steps are performed: 1% lidocaine with 1 : 100 000 epinephrine is injected submucoperichondrally bilaterally in the area of anticipated flap incision and elevation.

Greater palatine foramina injections are also performed for posterior hemostasis.

Standard Killian or hemitransfixion incisions are employed for the majority of deviations. Initial elevation of the flap is performed nonendoscopically using a Cottle or Freer elevator to sharply establish the subperichondrial plane. Once the plane has been established, a suction Freer elevator is used to simultaneously complete the flap dissection and aspirate blood for an optimal endoscopic view. A vertical incision is made full thickness through the cartilage several millimeters anterior to the point of maximal deflection, which typically lies at the junction between the quadrangular cartilage and the perpendicular plate of the ethmoid. The contralateral flap is then raised in a similar fashion. The deviated portions of cartilage and bone are then excised sharply. The flaps are then dissected inferiorly to the nasal floor in order to address deflections of the vomer.

Adequacy of the surgical correction can be assessed by returning the mucosal flaps to the midline and inspecting the nasal airway bilaterally while palpating areas of residual deviation. Once satisfactory correction has been achieved, the septal incision is closed with a simple interrupted absorbable 4.0 vicryl sutures. Disposable fingertip filled gauze inside packing smeared with tetracycline 1 % ophthalmic ointment is placed bilaterally to compress the flaps together. Anterior packings were removed after 48 hours postoperatively.

Endoscopic inferior turbinoplasty or turbinate reduction technique

A standard 0° sinus endoscope was used in all turbinoplasty procedures. The inferior turbinates were infiltrated with an intrathecal 22 gauge needle delivering lidocaine 1 % and 1:100 000 epinephrine solution, for additional anaesthesia and haemostasis. A longitudinal incision was made running inferiorly from the caudal end of the inferior turbinate up to the anterior portion, using a sickle knife or number 11 blade, and completed with turbinate scissors when necessary. The medial mucoperiosteal

layer of the turbinate was elevated from the bony part of the turbinate in an antero-posterior direction, and from the inferior to the superior border of the turbinate, using a Freer elevator and the tip of the suction tube. In cases in which the inferior incision failed to completely release the mucoperiosteal flap, we additionally used turbinate scissors to cut the bone.

After elevation of the flap, the turbinate bone was completely denuded on its medial surface. Turbinate scissors were introduced perpendicular to the dissected inferior turbinate and cut off an adequate volume of the turbinate, working in an antero-posterior direction. After partial excision of the turbinate bone with its attached lateral mucosa, the posterior end of the turbinate was cauterised to avoid late bleeding. The previously elevated medial mucosal flap was then laterally rotated and repositioned to cover the remaining denuded turbinate bone and mucosal stump.

This mucosal flap was secured in place by the introduction of a disposable glove fingertip packing and the whole unit smeared with tetracycline 1% ophthalmic ointment. The anterior packing was removed after 48 hours.

Pre and post-operative subjective and objective measurement

Pre- and postoperatively all patients were evaluated by Visual Analogue Scale (VAS) comprising a 10 cm linear scale in which patients rated their nasal obstruction, facial pain, anterior discharge, posterior discharge and olfaction (Figure 1).

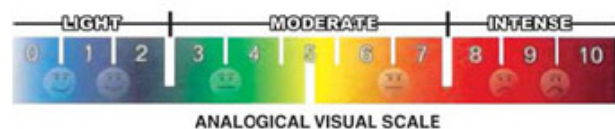


Figure 1. Visual analogue scale is used in conversion of subjective symptoms into scores.

Prior to the clinical examination (which included nasal endoscopy), peak nasal inspiratory flow (PNIF) measurements were performed using a Youtlen PNIFmeter (Clement Clark International) (Figure 2). The patient was seated, rested for 15 minutes and cautiously blew his nose. The airflow was measured bilaterally. Three readings were recorded for each of the measurements, but only the best was used for the

evaluation. All PNIF scores are expression in L/minute. Two and half months postoperatively the patients were recalled for a clinical examination. The patient were first evaluated by the postoperative version of the VAS followed by the bilateral PNIF and Glatzel mirror condensation measurements.

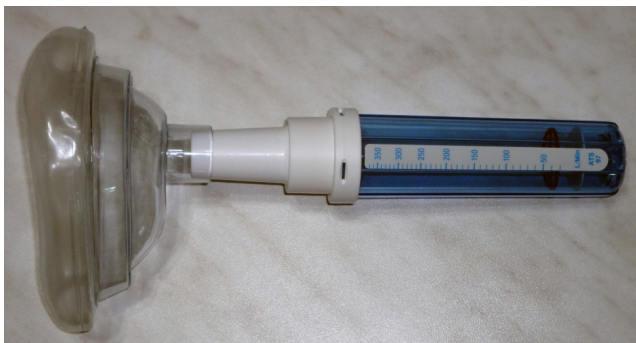

Figure 2. Peak nasal inspiratory flowmeter (Clement Clark International).

Glatzel mirror test

A Glatzel mirror which is specially made metal plates (Karl Storz 439200, 13 x 20 cm), as described by Gertner et al. [13] (Figure 3), were used for an objective assessment of nasal patency. Mirror measurements were done with seated subjects and the head in the orthostatic position. The metal plate was placed horizontally under the nostrils of participants, placing the mirror's zero point under the collumela.




Figure 3. The Glatzel mirror (Karl Storz 439200, 13x20 cm size).

Participants were asked to breathe slowly through both nostrils, with no inspiratory or expiratory effort, keeping the mouth and eyes closed. The first condensation was discarded

and the second condensation was marked with an overhead transparency-marking pen on the mirror itself and subsequently copied by transparency to standard paper. Care was taken when handling the plate to keep it from heating.

The condensation contour was measured along its greater and lesser axes and on the left and right sides.

The greater axis was obtained starting from the central point (zero mark) until the longest dimension (within the contour). The lesser axis was also selected. It was always perpendicular to the greater axis. The same ruler was used in all measurements (Trident triangular scalimeter - architect's scale - model ME-15/1). A second evaluator measured again the greater and lesser axes. New measurements were taken if the results did not coincide. Finally, the condensation area was calculated by using the mathematical formula for the ellipse ($S = a \times b \times \pi$.) proposed by Gertner et al [13] the sum of right and left nasal fossa unilateral values was calculated for the final assessment.

Statistical analysis

Continuous data were presented as means with standard deviations (SD) and categorical variables in numbers (percent) (Table 1). The non-parametric Wilcoxon signed-rank test was used to analyse pre- to postoperative changes (paired samples) in PNIF and the Glatzel mirror condensation square (Table 2, 3, 4). Group comparisons of pre and postoperative VAS and PNIF measures were performed by an independent samples t-test. A P-value less than 0.05 was considered statistically significant. All analyses were conducted using SPSS for Windows, version 19.0 (IBM Corp, Armonk, NY).

Ethical statement

The study was approved by the Research Ethics Committee of the Mongolian National University of Medical Sciences) (NO.13-03/1A). All patients provided written informed consent before participating in this study.

Results

Study population involvement

A total of 63 patients were followed up with 40 male (63.5 %), 23 female (36.5 %) and a mean age of 35.06 ± 11.36 years (95 % CI 16 – 64). Mean follow-up was 80 days. Patients with age group within 10 - 19 years were 1, 20 - 29 years were 27,

30 - 39 years were 16, 40 - 49 years were 8, 50 - 59 years were 10, 60 - 69 years were 1, respectively. There were 20 reported patients having had nasal allergic symptoms at one time or another during the past year. Also 35 patients reported past trauma history. Detailed information of participant's age groups and gender differences are shown in (Table 1).

Pre- and postoperative outcome measures

Table 2 demonstrates statistically significant reductions in subjective scores in VAS postoperatively.

When we performed non-parametric Wilcoxon signed rank test (paired samples), there was statistically significant improvement in each consecutive pre and postoperative subjective VAS scores (Nasal obstruction, head pain, anterior nasal discharge, posterior nasal discharge and olfaction) both endoscopic and conventional septoplasty with or without turbinate reduction performed groups (Table 2) (Figure 4). In

contrast when we checked by independent sample t-test there were no statistically significant differences (P-value was higher than 0.05) in mean pre and postoperative subjective VAS scores between the two (conventional and endoscopic) groups.

Preoperative septal deviated (convex or narrow) side air condensation square on Glatzel mirror were improved postoperatively in both endoscopic (14 mm²) and conventional (13 mm²) septoplasty with or without turbinate reduction groups, respectively (Table 3).

Same as before, there were no statistically significant differences in mean pre and postoperative objective Glatzel mirror measures in between two groups.

The significant bilateral PNIF improvements were observed in both endoscopic and conventional septoplasty with turbinate reduction groups (57 L/min) more than in septoplasty alone groups (48 L/min) (Table 4) (Figure 5).

Table 1. Descriptive statistics of participant's age and gender.

Variables	Male (n = 40)	Female (n = 23)	Total (n = 63)
	Mean ± SD	Mean ± SD	Mean ± SD
Age, years	35.1 ± 11.6	35.1 ± 11.2	35.1 ± 11.4
	N (%)	N (%)	N (%)
Age groups			
10-19	1 (2.5)	0 (0.0)	1 (1.6)
20-29	18 (45.0)	9 (39.1)	27 (42.9)
30-39	8 (20.0)	8 (34.8)	16 (25.4)
40-49	5 (12.5)	3 (13.0)	8 (12.7)
50-59	8 (20.0)	2 (8.7)	10 (15.9)
60-69	0 (0.0)	1 (4.3)	1 (1.6)
Allergic	13 (32.5)	7 (30.4)	20 (31.8)
Non-allergic	27 (67.5)	16 (69.6)	43 (68.2)
With trauma	27 (67.5)	8 (34.8)	35 (55.5)
Without trauma	13 (32.5)	15 (65.2)	28 (44.5)

Table 2. Pre- and postoperative subjective measures by VAS.

Septoplasty	Number	Preoperative	Postoperative	p value
		mean ± SD	mean ± SD	
Conventional				
Nasal obstruction	27	6.4 ± 2.0	0.2 ± 0.7	0.000
Head pain	27	3.1 ± 3.1	0.0 ± 0.0	0.000
Anterior nasal discharge	27	2.8 ± 3.0	0.6 ± 1.6	0.001
Posterior nasal discharge	27	2.9 ± 2.9	0.3 ± 0.9	0.001
Olfaction	27	1.2 ± 2.7	0.0 ± 0.0	0.041
Endoscopic				
Nasal obstruction	36	6.3 ± 2.5	0.3 ± 1.0	0.000
Head pain	36	4.4 ± 3.1	0.1 ± 0.3	0.000
Anterior nasal discharge	36	2.5 ± 2.4	0.3 ± 0.7	0.000
Posterior nasal discharge	36	2.6 ± 2.8	0.9 ± 1.6	0.006
Olfaction	36	2.2 ± 3.3	0.1 ± 0.7	0.002

VAS measured by visual analogue scale

Table 3. Pre- and postoperative septal deviated side (narrow or convex) condensation air square on Glatzel mirror.

Group	Number	Preoperative	Postoperative	p value
		mean ± SD	mean ± SD	
Conventional septoplasty with or without turbinate reduction	27	30.8 ± 13.0	44.9 ± 13.3	0.000
Endoscopic septoplasty with or without turbinate reduction	36	31.0 ± 11.0	43.5 ± 10.8	0.000
Total conventional and endoscopic septoplasty with or without turbinate reduction	63	30.9 ± 11.8	44.1 ± 11.9	0.000

Glatzel mirror condensation air measured in mm²

Table 4. Postoperative improvement of bilateral PNIF scores in septoplasty only and septoplasty with turbinate reduction groups.

Group	Number	Preoperative	Postoperative	p value
		mean ± SD	mean ± SD	
Conventional septoplasty	14	126.0 ± 47.8	179.4 ± 23.0	0.001
Endoscopic septoplasty	14	120.8 ± 50.5	164.3 ± 52.9	0.004
Total conventional and endoscopic septoplasty	28	123.4 ± 48.3	171.8 ± 40.7	0.0001
Conventional septoplasty with turbinate reduction	13	139.7 ± 37.3	193.5 ± 44.7	0.002
Endoscopic septoplasty with turbinate reduction	22	150.7 ± 48.3	209.6 ± 44.0	0.0001
Total conventional and endoscopic septoplasty with turbinate reduction	35	146.6 ± 44.3	203.6 ± 44.3	0.000

PNIF measured in l/min

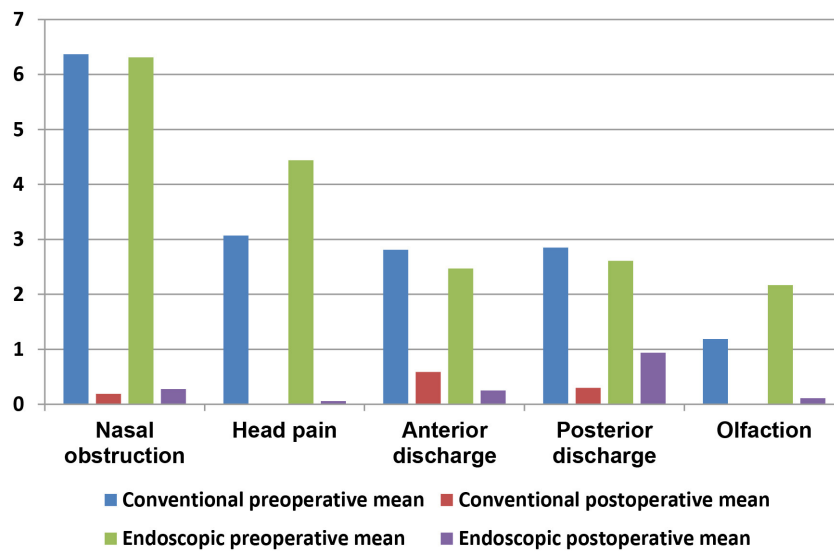


Figure 4. Pre- and postoperative subjective VAS measures in conventional and endoscopic septoplasty with or without turbinate reduction performed groups, respectively.

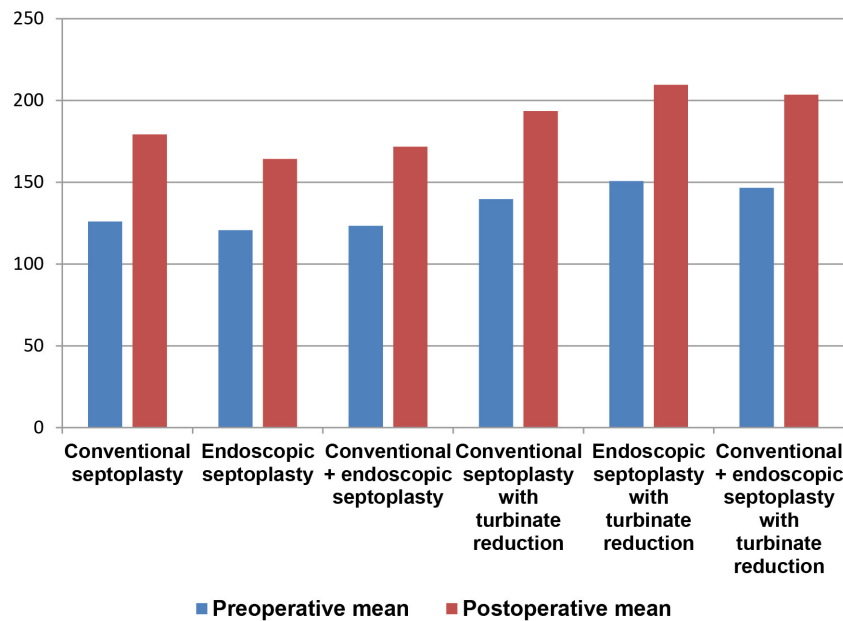


Figure 5. Postoperative improvements of bilateral nasal inspiratory peak flow measures in septoplasty and septoplasty with turbinate reduction performed groups (PNIF 1/min).

Discussion

One of the primary advantages of using the endoscope is superb visualization. Preoperatively, endoscopic examination allows for precise identification of septal pathology without anatomic distortion of the nasal airway from speculum

retraction. Intraoperatively, the endoscopes provide increased magnification, illumination and exposure compared to the views typically afforded by the standard headlight approach. Visualization of tissue planes, especially posteriorly, is excellent [14].

Endoscopic direct visualization aids in prevention and early

recognition of flap laceration. Limited flap dissection helps to decrease the overall risk of traumatic perforation.

In a series of 2730 power-assisted endoscopic septoplasties, De Sousa et al. [15] found a higher rate of success in preventing mucosal lacerations with endoscopic technique, resulting in a decreased risk of permanent perforation. The endoscopic dissection was found to be particularly useful in addressing septal spurs [11]. In cases of combined endoscopic septoplasty and endoscopic sinus surgery, the instrumentation is the same and thus makes the transition smooth. The endoscope can be readily passed into the nasal cavity to instantly assess improvements in access to the middle meatus [3, 4].

The superior visualization afforded by the endoscopes greatly enhances the operative teaching environment. When one teaches using the traditional headlight approach, didactic points are often left to verbal description. Literal blind faith is required in handing the procedure over to the resident in-training when it cannot be directly observed by the attending surgeon. In contrast, with endoscopic approaches, video projections allow resident technique to be carefully followed and critiqued, while scrub assistants can also follow the procedure and anticipate instrument needs [14].

In this pre and post study of the results of nasal septal surgery, we found statistically significant improvement in both subjective (VAS) and objective (Glatzel mirror and bilateral PNIF) measurements following nasal surgery whether septoplasty alone or septoplasty with turbinate reduction was performed. Septoplasty with turbinoplasty showed more improvement in all measurements than septoplasty alone like our previous research article [8]. We believe this may be due to the surgical removal of more of the skeletal structures in the nose when turbinate reduction is also performed.

In our study preoperative Glatzel mirror condensation air square at the nasal septal deviated side was increased after septoplasty with or without turbinate reduction in both conventional and endoscopic groups. In contrast there was no difference observed at the non deviated nasal passage postoperatively when we checked non-parametric Wilcoxon signed-rank test (paired samples). We believe it may be explained that straightened septum conditions symmetric airway passages in both sides of the nasal septum. Unfortunately there were few studies published related to use of Glatzel mirror test, but their results were not the same because they performed open

rhinoplasty instead of performing septoplasty [7].

The improvement in subjective scores after nasal surgery in our study is similar to other studies of nasal surgery [16 - 20] both for septoplasty alone and for septoplasty with turbinate reduction. They mostly used standard questionnaires NOSE, SNOT like our other study [8], but we used VAS for subjective scores in order to check its validation in this series. And it was well confirmed by our pre and postoperative results. It is beneficial for patients to see how their scores have improved following intervention. Especially visual analogue score is often thought to represent the best measure for identifying nasal obstruction [21]. Symptoms of chronic rhinosinusitis such as head pain, anterior and posterior nasal discharges were relieved postoperatively as VAS in this study. Obstruction of the osteomeatal complex due to severe septal deviation causes chronic rhinosinusitis by altering its mucociliary clearance function [22]. Our results may be explained by this hypothesis: septoplasty could be normalize nasal mucociliary clearance. In the long term, it may relieve the former symptoms related to chronic rhinosinusitis even without performing endoscopic sinus surgery.

VAS smell score improvement among the patients with hyposmia may be explained by an increase in

air flow and power in the nasal cavity as a result of the straightened septum. It is possible that this patient's smell level may have recovered due to the arrival of secondary smell molecules to the olfactory cleft as a result of the removal of a septal deviation that had prevented air flow to the olfactory region [23].

The improvement in bilateral PNIF values after overall conventional and endoscopic septoplasty pe groups was higher (48 l/min) than 2 other studies of Sahin's (25 L/min) [18] and Ozkul's (37.1 L/min) [19]. But the septoplasty with turbinate reduction group was more improved (57 L/min) than the septoplasty only groups in our study.

In our study, the overall mean preoperative bilateral PNIF score was lower (136 L/min) than the reference value of 138 L/min considered discriminative between obstructive and normal value [18], while the mean postoperative PNIF value (189 L/min) was well above this reference.

Compared to our study, the ratio of male to female was higher in two studies [18, 20] and different in one study (females were higher than males) [24].

The mean age was similar (63 patients with 35 years) across

all studies of Sahin [18] (60 patients with 31years), Andrews et al [20] (122 patients with 34 years) and Timperley et al [24] (51 patients with 36 years). Therefore, our sample seems to be demographically similar to other studies and likely representative of patients treated with septoplasty with or without turbinoplasty.

A limitation of our study is that we have not performed Glatzel mirror test and PNIF after decongestion and we recommend that this should be done in upcoming studies. In future studies in order to obtain more realistic results without effect of the physiologic nasal cycle and also to update this very first collected data series, we are planning to use decongestant on all patients before measuring unilateral (right and left) and bilateral PNIF pre and post operatively.

Conclusion

The application of endoscopic technology has helped enhance technical precision through vastly improved visualization. Furthermore, the endoscopic technique is valuable for the education of residents and fellows especially in university hospitals.

Our findings of pre- and postoperative subjective and objective improvements were significant in both endoscopic and conventional septoplasty with or without turbinate reduction.

However, there was no difference between endoscopic and conventional septoplasty with or without turbinate reduction pre- and postoperatively when we checked it by independent samples t-test.

In both groups septoplasty with turbinate reduction showed better improvement in breathing particularly with bilateral PNIF scores than septoplasty alone.

Conflict of Interest

The authors declare that they have no conflict of interest.

Acknowledgements

We would like to express our sincere gratitude to the University Central Hospital of Mongolian National University of Medical Sciences.

References

1. Sautter NB, Smith TL. Endoscopic septoplasty. *Otolaryngol Clin North Am* 2009; 42: 253-60.
2. Siegel NS, Gliklich RE, Taghizadeh F, Chang Y. Outcomes of septoplasty. *Otolaryngology Head Neck Surg* 2000; 122: 228-32.
3. Hwang PH, McLaughlin RB, Lanza DC, Kennedy DW. Endoscopic septoplasty: indications, technique, and results. *Otolaryngol Head Neck Surg* 1999; 120: 678-82.
4. Shah J, Roxbury CR, Sindwani R. Techniques in Septoplasty: Traditional Versus Endoscopic Approaches. *Otolaryngol Clin North Am* 2018; 51: 909-17.
5. Chung BJ, Batra PS, Citardi MJ, Lanza DC. Endoscopic septoplasty: revisitation of the technique, indications, and outcomes. *Am J Rhinol* 2007; 21: 307-11.
6. Brescovici S, Roithmann R. Modified Glatzel mirror test reproducibility in the evaluation of nasal patency. *Braz J Otorhinolaryngol* 2008; 74: 215-22.
7. de Pochat VD, Alonso N, Mendes RR, Gravina PR, Cronenberg EV, Meneses JV, et al. Assessment of nasal patency after rhinoplasty through the Glatzel mirror. *Int Arch Otorhinolaryngol* 2012; 16: 341-5.
8. Munkhbaatar P, Han YH, Tsogtjargal G, Tamir L, Ganchimeg P. Postoperative subjective and objective evaluation of septoturbinoplasty surgery in Mongolian patients with nasal obstruction symptom. *Cent Asian J Med* 2021; 7: 321-9.
9. Ottaviano G, Lund VJ, Nardello E. Comparison between unilateral PNIF and rhinomanometry in healthy and obstructed noses. *Rhinology* 2014; 52: 25-30.
10. Bermuller C, Kirsche H, Rettinger G, Riechelmann H. Diagnostic accuracy of peak nasal inspiratory flow and rhinomanometry in functional rhinosurgery. *Laryngoscope* 2008; 118: 605-10.
11. Lemonnier LA. Endoscopic septoplasty. *Oper Tech Otolaryngology* 2014; 25: 156-9.
12. Trimarchi M, Bellini C, Toma S, Bussi M. Back-and-forth endoscopic septoplasty: analysis of the technique and outcomes. *Int Forum Allergy Rhinol* 2012; 2: 40-4.
13. Gertner R, Podoshin L, Fradis M. A simple method of measuring the nasal airway in clinical work. *J Lar Otol* 1984; 98: 351-5.

14. Getz AE, Hwang PH. Endoscopic septoplasty. *Curr Opin Otolaryngology Head Neck Surg* 2008; 16: 26-31.
15. Sousa A, Inicarte L, Levine H. Powered Endoscopic Nasal Septal Surgery. *Acta Med Port* 2005; 18: 249-55.
16. Patel B, Virk JS, Randhawa PS, Andrews PJ. The internal nasal valve: a validated grading system and operative guide. *Eur Arch Oto Rhino L* 2018; 275: 2739-44.
17. Dosen LK, Kvinnesland K, TarAngen M, Shiryaeva O, Gay C, Haye R, et al. Unilateral and Bilateral PNIF in Quality Control of Nasal Septal Surgery. *Int J Otolaryngol* 2018; 84-8.
18. Sahin C. Evaluation of Patient Satisfaction After Nasal Septoplasty Operation Using Peak Nasal Inspiratory Flow and Nasal Obstruction Symptom Score Questionnaire. *J Craniofacial Surg* 2016; 27: 1289-91.
19. Ozkul HM, Balikci HH, Gurdal MM. Normal range of peak nasal inspiratory flow and its role in nasal septal surgery. *J Craniofac Surg* 2013; 24: 900-2.
20. Andrews PJ, Choudhury N, Takhar A, Poirrier AL, Jacques T, Randhawa PS, et al. The need for an objective measure in septorhinoplasty surgery: are we any closer to finding an answer? *Clin Otolaryngology* 2015; 40: 698-703.
21. Ciprandi G, Mora F, Cassano M, Gallina AM, Mora R. Visual analog scale (VAS) and nasal obstruction in persistent allergic rhinitis. *Otolaryngol Head Neck Surg* 2009; 141: 527-9.
22. Bayiz U, Dursun E, Islam A. Is septoplasty alone adequate for the treatment of chronic rhinosinusitis with septal deviation? *Am J Rhinol* 2005; 19: 612-6.
23. Kilicaslan A, Acar GO, Tekin M, Ozdamar OI. Assessment the long-term effects of septoplasty surgery on olfactory function. *Acta Otolaryngol* 2016; 136: 1079-84.
24. Timperley D, Srubisky A, Stow N, Marcellis GN, Harvey RJ. Minimal clinically important differences in nasal peak inspiratory flow. *Rhinology* 2011; 49: 37-40.