

The Detection of Human Papillomavirus 16 and 18 Type L1 Capsid Protein in Cervical Lesion Specimens Among Mongolian Women

Uranbolor Jugder¹, Erdenetsogt Dongobat², Galtsog Lodon², Jav Baldan¹, Sarantuya Jav³

¹Department of Obstetrics and Gynecology, School of Medicine, Mongolian National University of Medical Sciences, Ulaanbaatar, Mongolia; ²Department of Pathology, School of Pharmacy and Biomedicine, Mongolian National University of Medical Sciences, Ulaanbaatar, Mongolia; ³Department of Molecular Biology and Genetics, School of Pharmacy and Biomedicine, Mongolian National University of Medical Sciences, Ulaanbaatar, Mongolia

Submitted: July 8, 2015

Revised: September 15, 2015

Accepted: September 30, 2015

Corresponding Author

Uranbolor Jugder, MD, MSc
Department of Obstetrics and
Gynecology, School of Medicine,
Mongolian National University
of Medical Sciences, Zorig Street,
Ulaanbaatar, Mongolia.

Tel: +976-9908-6373

E-mail: uranbolor@gmail.com

This is an Open Access article distributed under the terms of the Creative Commons Attribution Non-Commercial License (<http://creativecommons.org/licenses/bync/3.0/>) which permits unrestricted non-commercial use, distribution, and reproduction in any medium, provided the original work is properly cited. Copyright© 2015 Mongolian National University of Medical Sciences

Objectives: The goal of this study is to evaluate expression of the HPV16/18 L1 in cervical tissues in correlation with lesion grade. **Methods:** A total of 96 specimens were analyzed in this study. There were 50 cases diagnosed as low-grade squamous intraepithelial lesion (LSIL) and 46 cases diagnosed as high-grade (H-) SIL. All cases were submitted for immunohistochemistry with anti-HPV16 /18 L1 antibody. **Results:** The positive rate of HPV16 L1 and HPV18 L1 was identified in 61 (64%) and 21 (22%) of all cases. There was a statistically significant difference for HPV18 ($X^2 = 0.599$, $p < 0.05$), but not for HPV16 ($X^2 = 0.024$, $p > 0.05$) in the two SIL groups. In addition, 27 cases had no HPV16/18 L1 expression and 13 cases had HPV16/18 L1 co-expression. **Conclusion:** Lack of HPV L1 capsid protein in cervical lesions may serve as a prognostic marker of enhanced malignant potential. There is still a critical need to find other molecular surrogate markers, which can provide accurate information about which precursor lesions would progress toward cancer.

Keywords: Human Papillomavirus 16, L1 Protein, Human Papillomavirus Type 18, Squamous Intraepithelial Lesions of the Cervix

Introduction

Cervical cancer is the fourth-most common type of cancer in women worldwide [1] and also the second-most common female malignancy in Mongolia [2]. A subset of HPV types are the causative agents of cervical cancer, since 99% of tumors are positive for HPV-DNA [3]. Infection of the cervix uteri by HPV can initially result in mild dysplasia termed low-grade squamous intraepithelial lesion (LSIL) or cervical intraepithelial neoplasia

grade I (CINI). These lesions exhibit only mildly-altered patterns of differentiation and many of them are cleared by the immune system in less than a year [4]. But some of the infections are not cleared by the immune system and can persist for periods as long as several decades. Persistence of infection by high-risk HPV types is the greatest risk for development of cervical cancer. Currently, neither cytology nor HPV DNA typing can provide accurate information about which precursor lesion would progress toward cancer [5, 6]. Recently, some reports showed

that L1 capsid protein could be a new powerful and useful marker for revealing the status of productive HPV infections [7-9].

L1 capsid protein comprises 90% of HPV viral surface proteins and is typically expressed during the late phase of viral replication [10]. Thus far, most immunochemical studies on the HPV L1 capsid protein have investigated the predictive role of the protein in squamous intraepithelial lesions [11-13]. Although cervical cancer has been extensively studied among Mongolian women, the high-risk HPV L1 has not been analyzed in cervical pre-cancer tissue yet. In this study, our team detected the L1 capsid protein of HPV16 and HPV18 using immunohistochemistry (IHC) and investigated the difference in two pathological groups.

Materials and Methods

1. Research sample

A total of 96 paraffin-embedded cervical tissues were obtained from the National Cancer Center of Mongolia, from January until December 2013. There were 50 cases diagnosed as LSIL and 46 cases diagnosed as high-grade (H-) SIL. The average age was 40.6 years (range: 22-61 years). All of the patients had the same results by cytology and histology and cervical tissues were big enough to use IHC. None of the patients had received hormone therapy, chemotherapy, radiotherapy or had been diagnosed with other HPV-related cancers. The study was approved by the medical research ethics committee of the Mongolian National University of Medical Sciences and informed consent was obtained from all patients. Paraffin-embedded cervical tissues were processed at the time of diagnosis and IHC was done at the laboratory of the Pathology Department of the Mongolian National University of Medical Sciences. All of the 96 cases were submitted for IHC with anti-HPV16 L1 antibody (Concentrated Mouse monoclonal [camvir-1] to HPV16 L1, Biocare Medical) and anti-HPV18 L1 antibody (Mouse monoclonal [5A3], Ab cam ab 49490).

2. Immunohistochemistry

From paraffin-embedded tissues 4- μ m sections were cut, mounted on glass pretreated with 2% 3-aminopropyltriethoxysilane (Sigma), and air-dried overnight at 37°C. Sections were deparaffinized in xylene, hydrated in a graded alcohol series and subsequently washed with distilled water. Briefly, sections were

incubated for 15 minutes in boiling citrate buffer, cooled down in buffer for 20 minutes, and subsequently incubated overnight at room temperature with the first antibody. Binding of the mAb was detected using an anti-mouse ABC system. Antibody binding was revealed using biotinylated secondary antibodies, avidin-peroxidase and diaminobenzidine substrate. Slides were counterstained with hematoxylin, dehydrated before mounting and observed with a microscope equipped with bright-field illumination. Histology for all sections was analyzed by two pathologists independently. A positive and a negative control were run with every batch of IHC staining done. IHC staining of the cervical tissue was implemented to allow semi-quantitative analysis on the IHC stained slides. Staining density for each antibody was semi-quantified into three main categories based on the percentage of cells being stained positive: (-) = no cells stained positive or = <10% of the cells stained positive, (+) = 10-50% stained positive, (++) = 50-90% stained positive.

3. Statistics analysis

Statistical analysis was performed by Chi-Square test using SPSS 17.0. A probability value of <0.05 was considered to indicate statistical significance.

Results

IHC staining for HPV16 and HPV18 were completed for all 96 cases (100%). Results showed that with an increase of histological grade, the L1 protein expression had a decreasing tendency. Positive staining of L1 was observed within the nuclear or cytoplasmic subcellular regions (Figure 1, 2).

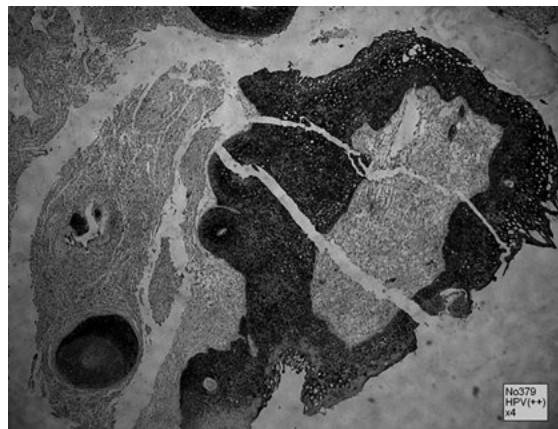


Figure 1. Positive staining for HPV16 L1 in LSIL specimen. Positive cells show dark, nuclear and cytoplasmic staining.

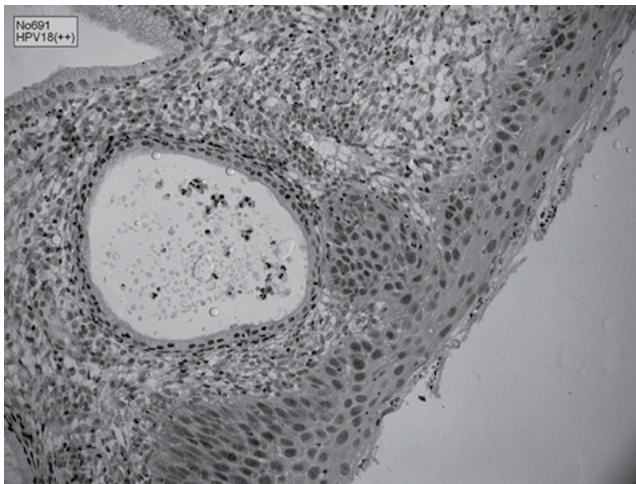


Figure 2. Positive staining for HPV18 L1 in LSIL specimen. Positive cells show dark, nuclear staining.

HPV16 L1 was positively identified in 64% (61/96) of cases. L1 capsid protein was expressed in 37 of the 50 LSIL cases (74%), 24 of the 46 HSIL cases (52%). The expression of L1 in the LSIL group was higher than in the HSIL group, but there was not a significant difference between two groups (Table 1).

HPV18 L1 was positively identified in 22% (21/96) of cases. The HPV18 L1 capsid protein was expressed in 12 of the 50 LSIL cases (24%) and 9 out of 46 HSIL cases (20%). The HPV18 L1 expression was negatively related to the grade of cervical lesions. There was a significant difference for HPV18 L1 capsid protein in HSIL and LSIL groups (Table 1).

Also, 27 cases had no HPV16/18 L1 expression and 13 cases had HPV16/18 L1 co-expression.

Table 1. Chi-square test results for HPV L1 in different pathologic groups

HPV subtypes		Pathology groups		Chi-square; p-value
		LSIL (%)	HSIL (%)	
HPV16	negative	13 (26)	22 (48)	0.024; p>0.05
	positive	37 (74)	24 (52)	
HPV18	negative	38 (76)	37 (80)	0.599; p<0.05
	positive	12 (24)	9 (20)	

Discussion

Although the incidence of cervical cancer worldwide is decreasing, it is still an important health care problem in the

developing countries. While cervical cancer screening relies on cervical cytology and high-risk HPV detection, the histologic diagnosis, and specifically lesion grade, is the main parameter that drives clinical management of screened-positive women. Recently, some researchers suggested that the HPV L1 capsid protein could be used as a marker for revealing the status of productive HPV infections. HPV L1 capsid protein, the major structural protein of HPV, is expressed in the early productive phase of cervical cancer, but is gradually lost in the later proliferative phase when HPV DNA is integrated into the host DNA [14].

A number of recent studies have evaluated the expression of major capsid protein L1 in cytologic specimens. The results have shown that 30%-75% of LSILs and 33%-40% of HSILs express L1 capsid protein. [7, 9, 10, 15-17]. Some of these studies evaluated the prognostic utility of L1 immunocytochemistry on a Pap sample in predicting lesion behavior. Most of the studies that relied on cytologic regression with variable length of follow-up associated the presence of L1 expression with clinical regression. IHC results of studies show the positive rate of HPV L1 protein is increasing while the pathologic grade is decreasing. Most of them suggested to detect combined expression of p16 and HPV L1 protein in different pathological groups [18-20]. These results suggest that HPV L1 positivity in LSIL with HPV16 infection might be attributable to the effect of the L1 protein on keratinocytes infected with other high-risk HPV types. In the present study, the positive rate of HPV18 L1 decreased with the increase in histological grade. Despite this statistically significantly difference between the two histological-grade groups of HPV18 L1 capsid protein, more research is needed to determine if a clinically significant differences exist.

Our research had some limitations that may be that the sample size was small and we only detected two high-risk HPV types. Therefore, the number of specimens containing adjacent lesions of different grades is too small for drawing meaningful conclusions. Nonetheless, a hypothesis is suggested by this observation, namely, that the presence of L1 expression might be used as a marker which can indicate low-risk pattern. In the future, there is still a critical need to find other molecular surrogate markers, which can provide accurate information about which precursor lesions would progress toward cancer.

Conflict of interest

The authors state no conflict of interest.

References

- IARC. Globocan 2012 cancer fact sheet [accessed on July 2015]. Available at: <http://www.globocan.iarc.fr/>
- National Cancer Center of Mongolia. Cancer distribution in Mongolia [accessed on July 2015]. Available at: <http://www.cancer-center.gov.mn/>
- Walboomers JM, Jacobs MV, Manos MM, et al. Human papillomavirus is a necessary cause of invasive cervical cancer worldwide. *J Pathol* 1999; 189(1):12–19.
- Hopfl R, Heim K, Christensen N, et al. Spontaneous regression of CIN and delayed type hypersensitivity to HPV-16 oncoprotein E7. *Lancet* 2000; 356(9246):1985-1986.
- Ostor AG. Natural history of cervical intraepithelial neoplasia: a critical review. *Int J Gynecol Pathol* 1993; 12(2):186-192.
- Klaes R, Benner A, Friedrich T, et al. p16INK4a immunohistochemistry improves interobserver agreement in the diagnosis of cervical intraepithelial neoplasia. *Am J Surg Pathol* 2002; 26(11):1389-1399.
- Melsheimer P, Kaul S, Dobeck S, Bastert G. Immunocytochemical detection of HPV high-risk type L1 capsid proteins in LSIL and HSIL as compared with detection of HPV L1 DNA. *Acta Cytol* 2003; 47(2):124–128.
- Griesser H, Sander H, Walczak C, Hilfrich R. Immunochemical detection of HPV L1 capsid protein: prognostic marker for early squamous lesions of the cervix. *Acta Cytol* 2007; 52:268.
- Rauber D, Mehlhorn G, Fasching PA, Beckmann MW, Ackermann S. Prognostic significance of the detection of human papilloma virus L1 protein in smears of mild to moderate cervical intraepithelial lesions. *Eur J Obstet Gynecol Reprod Biol* 2008; 140(2):258–262.
- Gu W, Ding J, Wang X, et al. Generalized substitution of iso encoding codons shortens the duration of papillomavirus L1 protein expression in transiently gene-transfected keratinocytes due to cell differentiation. *Nucleic Acids Res* 2007; 35(14):4820-4832.
- Lee SJ, Lee AW, Kim TJ, et al. Correlation between immunocytochemistry of human papilloma virus L1 capsid protein and behavior of low-grade cervical cytology in Korean women. *J Obstet Gynaecol Res* 2011; 37(9):1222-1228.
- Negri G, Bellisano G, Zannoni GF, et al. p16 ink4a and HPV L1 immunohistochemistry is helpful for estimating the behavior of low-grade dysplastic lesions of the cervix uteri. *Am J Surg Pathol* 2008; 32(11):1715-1720.
- Griesser H, Sander H, Walczak C, Hilfrich RA. HPV vaccine protein L1 predicts disease outcome of high-risk HPV+ early squamous dysplastic lesions. *Am J Clin Pathol* 2009; 132(6): 840-845.
- Doorbar J. The papillomavirus life cycle. *J Clin Virol* 2005; 32 Suppl 1:S7-15.
- Lee H, Lee KJ, Jung CK, et al. Expression of HPV L1 capsid protein in cervical specimens with HPV infection. *Diagn Cytopathol* 2008; 36(12):864–867.
- Xiao W, Bian M, Ma L, et al. Immunochemical analysis of human papillomavirus L1 capsid protein in liquid-based cytology samples from cervical lesions. *Acta Cytol* 2010; 54(5):661–667.
- Yu L, Wang L, Zhong J, Chen S. Diagnostic value of p16INK4A, Ki-67 and human papillomavirus L1 capsid protein immunochemical staining on cell blocks from residual liquidbased gynecologic cytology specimens. *Cancer Cytopathol* 2010; 118(1):47–55.
- Song Y, Li Q, Li L, et al. Expression and clinical values of HPV L1 and p16INK4a protein in uterine cervical lesions. *Zhonghua Zhong Liu Za Zhi* 2012; 34(5):352-355.
- Gatta LB, Berenzi A, Balzarini P, et al. Diagnostic implications of L1, p16, and Ki-67 proteins and HPV DNA in low-grade cervical intraepithelial neoplasia. *Int J Gynecol Pathol* 2011; 30(6):597-604.
- Balan R, Giusca S, Caruntu ID, Gheorghita V, Neacsu D, Amalinei C. Immunochemical assessment of p16 and HPV L1 capsid protein in cervical squamous intraepithelial lesions. *Rev Med Chir Soc Med Nat Iasi* 2010; 114(4):1118-1124.